

CLINICAL PRACTICE GUIDELINES

ROBROY L. MARTIN, PT, PhD • RUTH CHIMENTI, DPT, PhD • TYLER CUDDEFORD, PT, PhD • JEFF HOUCK, PT, PhD
J.W. MATHESON, DPT • CHRISTINE M. MCDONOUGH, PT, PhD • STEPHEN PAULSETH, DPT, MS
DANE K. WUKICH, MD • CHRISTOPHER R. CARCIA, PT, PhD

Achilles Pain, Stiffness, and Muscle Power Deficits: Midportion Achilles Tendinopathy Revision 2018

*Clinical Practice Guidelines Linked to the
International Classification of Functioning,
Disability and Health From the Orthopaedic Section
of the American Physical Therapy Association*

J Orthop Sports Phys Ther. 2018;48(5):A1-A38. doi:10.2519/jospt.2018.0302

SUMMARY OF RECOMMENDATIONS.....	A2
INTRODUCTION.....	A3
METHODS.....	A4
CLINICAL GUIDELINES: <i>Impairment/Function-Based Diagnosis</i>	A7
CLINICAL GUIDELINES: <i>Examination</i>	A14
CLINICAL GUIDELINES: <i>Interventions</i>	A15
AUTHOR/REVIEWER AFFILIATIONS AND CONTACTS	A20
REFERENCES	A21

REVIEWERS: Paul Beattie, PT, PhD • Yu-Jen Chang, PhD • John DeWitt, DPT • Amanda Ferland, DPT
Sandra Kaplan, PT, PhD • David Killoran, PhD • Leslie Torburn, DPT

For author, coordinator, contributor, and reviewer affiliations, see end of text. ©2018 Orthopaedic Section, American Physical Therapy Association (APTA), Inc, and the Journal of Orthopaedic & Sports Physical Therapy. The Orthopaedic Section, APTA, Inc, and the Journal of Orthopaedic & Sports Physical Therapy consent to the reproduction and distribution of this guideline for educational purposes. Address correspondence to Brenda Johnson, ICF-Based Clinical Practice Guidelines Coordinator, Orthopaedic Section, APTA, Inc, 2920 East Avenue South, Suite 200, La Crosse, WI 54601. E-mail: icf@orthopt.org

Summary of Recommendations*

DIAGNOSIS/CLASSIFICATION

C In addition to the arc sign and Royal London Hospital test, clinicians can use a subjective report of pain located 2 to 6 cm proximal to the Achilles tendon insertion that began gradually and pain with palpation of the midportion of the tendon to diagnose midportion Achilles tendinopathy.

EXAMINATION – OUTCOME MEASURES: ACTIVITY LIMITATIONS/SELF-REPORTED MEASURES

A Clinicians should use the Victorian Institute of Sport Assessment-Achilles (VISA-A) to assess pain and stiffness, and either the Foot and Ankle Ability Measure (FAAM) or the Lower Extremity Functional Scale (LEFS) to assess activity and participation in patients with a diagnosis of midportion Achilles tendinopathy.

EXAMINATION – ACTIVITY LIMITATIONS/PHYSICAL PERFORMANCE MEASURES

B Clinicians should use physical performance measures, including hop and heel-raise endurance tests, as appropriate, to assess a patient's functional status and document findings.

EXAMINATION – PHYSICAL IMPAIRMENT MEASURES

B When evaluating physical impairment over an episode of care for those with Achilles tendinopathy, one should measure ankle dorsiflexion range of motion, subtalar joint range of motion, plantar flexion strength and endurance, static arch height, forefoot alignment, and pain with palpation.

INTERVENTIONS – EXERCISE

A Clinicians should use mechanical loading, which can be either in the form of eccentric exercise, or a heavy-load, slow-speed (concentric/eccentric) exercise program, to decrease pain and improve function for patients with midportion Achilles tendinopathy without presumed frailty of the tendon structure.

F Patients should exercise at least twice weekly within their pain tolerance.

INTERVENTIONS – STRETCHING

C Clinicians may use stretching of the ankle plantar flexors with the knee flexed and extended to reduce pain and improve satisfaction with outcome in patients with midportion Achilles tendinopathy who exhibit limited ankle dorsiflexion range of motion.

INTERVENTIONS – NEUROMUSCULAR RE-EDUCATION

F Clinicians may use neuromuscular exercises targeting lower extremity impairments that may lead to abnormal kinetics and/or kinematics, specifically eccentric overload of the Achilles tendon during weight-bearing activities.

INTERVENTIONS – MANUAL THERAPY

F Clinicians may consider using joint mobilization to improve mobility and function and soft tissue mobilization to increase range of motion for patients with midportion Achilles tendinopathy.

INTERVENTIONS – PATIENT EDUCATION: ACTIVITY MODIFICATION

B For patients with nonacute midportion Achilles tendinopathy, clinicians should advise that complete rest is not indicated and that they should continue with their recreational activity within their pain tolerance while participating in rehabilitation.

INTERVENTIONS – PATIENT COUNSELING

E Clinicians may counsel patients with midportion Achilles tendinopathy. Key elements of patient counseling could include (1) theories supporting use of physical therapy and role of mechanical loading, (2) modifiable risk factors, including body mass index and footwear, and (3) typical time course for recovery from symptoms.

INTERVENTIONS – HEEL LIFTS

D Because contradictory evidence exists, no recommendation can be made for the use of heel lifts in patients with midportion Achilles tendinopathy.

INTERVENTIONS – NIGHT SPLINTS

C Clinicians should not use night splints to improve symptoms in patients with midportion Achilles tendinopathy.

INTERVENTIONS – ORTHOSES

D Because contradictory evidence exists, no recommendation can be made for the use of orthoses in patients with midportion Achilles tendinopathy.

INTERVENTIONS – TAPING

F Clinicians should not use therapeutic elastic tape to reduce pain or improve functional performance in patients with midportion Achilles tendinopathy.

F Clinicians may use rigid taping to decrease strain on the Achilles tendon and/or alter foot posture in patients with midportion Achilles tendinopathy.

INTERVENTIONS – LOW-LEVEL LASER THERAPY

D Because contradictory evidence exists, no recommendation can be made for the use of low-level laser therapy in patients with midportion Achilles tendinopathy.

INTERVENTIONS – IONTOPHORESIS

B Clinicians should use iontophoresis with dexamethasone to decrease pain and improve function in patients with acute midportion Achilles tendinopathy.

INTERVENTIONS – DRY NEEDLING

F Clinicians may use combined therapy of dry needling with injection under ultrasound guidance and eccentric exercise to decrease pain for individuals with symptoms greater than 3 months and increased tendon thickness.

*These recommendations and clinical practice guidelines are based on the scientific literature published prior to November 2017.

List of Abbreviations

APTA: American Physical Therapy Association

BMI: body mass index

CI: confidence interval

CPG: clinical practice guideline

DECT: dual-energy computed tomography

ESWT: extracorporeal shockwave therapy

FAAM: Foot and Ankle Ability Measure

HVIGI: high-volume image-guided injection

ICD: International Classification of Diseases

ICF: International Classification of Functioning, Disability and Health

JOSPT: *Journal of Orthopaedic & Sports Physical Therapy*

LEFS: Lower Extremity Functional Scale

LLLT: low-level laser therapy

LOINC: Logical Observation Identifiers Names and Codes

MRI: magnetic resonance imaging

mRNA: messenger ribonucleic acid

MSU: monosodium urate

NPRS: numeric pain-rating scale

PRP: platelet-rich plasma

US: ultrasound

VAS: visual analog scale

VISA-A: Victorian Institute of Sport Assessment-Achilles

Introduction

AIM OF THE GUIDELINES

The Orthopaedic Section of the American Physical Therapy Association (APTA) has an ongoing effort to create evidence-based clinical practice guidelines (CPGs) for orthopaedic physical therapy management of patients with musculoskeletal impairments described in the World Health Organization's International Classification of Functioning, Disability and Health (ICF).

The purposes of these clinical guidelines are to:

- Describe evidence-based physical therapy practice, including diagnosis, prognosis, intervention, and assessment of outcome for musculoskeletal disorders commonly managed by orthopaedic physical therapists
- Classify and define common musculoskeletal conditions using the World Health Organization's terminology related to impairments of body function and body structure, activity limitations, and participation restrictions
- Identify interventions supported by current best evidence to address impairments of body function and structure, activity limitations, and participation restrictions associated with common musculoskeletal conditions
- Identify appropriate outcome measures to assess changes resulting from physical therapy interventions in body function and structure as well as in activity and participation of the individual
- Provide a description to policy makers, using internationally accepted terminology, of the practice of orthopaedic physical therapists

- Provide information for payers and claims reviewers regarding the practice of orthopaedic physical therapy for common musculoskeletal conditions
- Create a reference publication for orthopaedic physical therapy clinicians, academic instructors, clinical instructors, students, interns, residents, and fellows regarding the best current practice of orthopaedic physical therapy

STATEMENT OF INTENT

These guidelines are not intended to be construed or to serve as a standard of medical care. Standards of care are determined on the basis of all clinical data available for an individual patient and are subject to change as scientific knowledge and technology advance and patterns of care evolve. These parameters of practice should be considered guidelines only. Adherence to them will not ensure a successful outcome in every patient, nor should they be construed as including all proper methods of care or excluding other acceptable methods of care aimed at the same results. The ultimate judgment regarding a particular clinical procedure or treatment plan must be made based on clinician experience and expertise in light of the clinical presentation of the patient, the available evidence, available diagnostic and treatment options, and the patient's values, expectations, and preferences. However, we suggest that significant departures from accepted guidelines should be documented in the patient's medical records at the time the relevant clinical decision is made.

Methods

Content experts with relevant physical therapy, medical, and surgical expertise were appointed by the Orthopaedic Section, APTA to conduct a review of the literature and to develop an updated Achilles Pain, Stiffness, and Muscle Power Deficits: Midportion Achilles Tendinopathy CPG as indicated by the current state of the evidence in the field. The aims of the revision were to provide a concise summary of the evidence since publication of the original guideline and to develop new recommendations or revise previously published recommendations to support evidence-based practice. The authors of this guideline revision worked with the CPG Editors and medical librarians for methodological guidance. The research librarians were chosen for their expertise in systematic review and rehabilitation literature search and to perform systematic searches for concepts associated with classification, examination, and intervention strategies for Achilles Pain, Stiffness, and Muscle Power Deficits: Midportion Achilles Tendinopathy.²² Briefly, the following databases were searched from 2009 to November 2017: MEDLINE, CINAHL, Cochrane Library, and PEDro (see **APPENDIX A** for full search strategies and **APPENDIX B** for search dates and results, available at www.orthopt.org).

The authors declared relationships and developed a conflict management plan, which included submitting a Conflict of Interest form to the Orthopaedic Section, APTA, Inc. Articles that were authored by a reviewer were assigned to an alternate reviewer. Funding was provided to the CPG development team for travel and expenses for CPG development training by the Orthopaedic Section, APTA, Inc. The CPG development team maintained editorial independence.

Articles contributing to recommendations were reviewed based on specified inclusion and exclusion criteria with the goal of identifying evidence relevant to physical therapist clinical decision making for adults with Achilles Pain, Stiffness, and Muscle Power Deficits: Midportion Achilles Tendinopathy. The title and abstract of each article were reviewed independently by 2 members of the CPG development team for inclusion (see **APPENDIX C** for inclusion and exclusion criteria, available at www.orthopt.org). Full-text review was then similarly conducted to obtain the final set of articles for contribution to recommendations. The team leader (R.L.M.) provided the final decision for discrepancies that were not resolved by the review team (see **APPENDIX D** for flow chart of articles and **APPENDIX E** for articles included in recommendations by topic, available at www.orthopt.org). For selected relevant topics that were not appropriate for the development

of recommendations, such as incidence and imaging, articles were not subject to a systematic review process and were not included in the flow chart. Evidence tables for this CPG are available on the Clinical Practice Guidelines page of the Orthopaedic Section of the APTA website: www.orthopt.org.

This guideline was issued in 2018 based on the published literature up through November 2017. This guideline will be considered for review in 2022, or sooner if new evidence becomes available. Any updates to the guideline in the interim period will be noted on the Orthopaedic Section of the APTA website: www.orthopt.org.

LEVELS OF EVIDENCE

Individual clinical research articles were graded according to criteria adapted from the Centre for Evidence-Based Medicine, Oxford, United Kingdom for diagnostic, prospective, and therapeutic studies.¹⁴⁹ In teams of 2, each reviewer independently assigned a level of evidence and evaluated the quality of each article using a critical appraisal tool (see **APPENDICES F** and **G** for Levels of Evidence table and details on procedures used for assigning levels of evidence, available at www.orthopt.org). The evidence update was organized from highest level of evidence to lowest level. An abbreviated version of the grading system is provided below.

I	Evidence obtained from systematic reviews, high-quality diagnostic studies, prospective studies, or randomized controlled trials
II	Evidence obtained from systematic reviews, lesser-quality diagnostic studies, prospective studies, or randomized controlled trials (eg, weaker diagnostic criteria and reference standards, improper randomization, no blinding, less than 80% follow-up)
III	Case-control studies or retrospective studies
IV	Case series
V	Expert opinion

GRADES OF EVIDENCE

The strength of the evidence supporting the recommendations was graded according to the previously established methods for the original guideline and those provided below. Each team developed recommendations based on the strength of evidence, including how directly the studies addressed the question of Achilles Pain, Stiffness, and Muscle Power Deficits: Midportion Achilles Tendinopathy. In developing their recommendations, the authors considered the strengths and limitations of the body of evidence and the health benefits, side effects, and risks of tests and interventions.

Methods (*continued*)

GRADES OF RECOMMENDATION		STRENGTH OF EVIDENCE
A	Strong evidence	A preponderance of level I and/or level II studies support the recommendation. This must include at least 1 level I study
B	Moderate evidence	A single high-quality randomized controlled trial or a preponderance of level II studies support the recommendation
C	Weak evidence	A single level II study or a preponderance of level III and IV studies, including statements of consensus by content experts, support the recommendation
D	Conflicting evidence	Higher-quality studies conducted on this topic disagree with respect to their conclusions. The recommendation is based on these conflicting studies
E	Theoretical/foundational evidence	A preponderance of evidence from animal or cadaver studies, from conceptual models/principles, or from basic science/bench research support this conclusion
F	Expert opinion	Best practice based on the clinical experience of the guidelines development team

GUIDELINE REVIEW PROCESS AND VALIDATION

Identified reviewers who are experts in Achilles tendinopathy management and rehabilitation reviewed the CPG draft for integrity, accuracy, and to ensure that it fully represented the current evidence for the condition. The guideline draft was also posted for public comment and review

on www.orthopt.org, and a notification of this posting was sent to the members of the Orthopaedic Section, APTA, Inc. In addition, a panel of consumer/patient representatives and external stakeholders, such as claims reviewers, medical coding experts, academic educators, clinical educators, physician specialists, and researchers, also reviewed the guideline. All comments, suggestions, and feedback from the expert reviewers, public, and consumer/patient representatives were provided to the authors and editors for consideration and revisions. Guideline development methods, policies, and implementation processes are reviewed at least yearly by the Orthopaedic Section, APTA's ICF-Based Clinical Practice Guideline Advisory Panel, including consumer/patient representatives, external stakeholders, and experts in physical therapy practice guideline methodology.

DISSEMINATION AND IMPLEMENTATION TOOLS

In addition to publishing these guidelines in the *Journal of Orthopaedic & Sports Physical Therapy (JOSPT)*, these guidelines will be posted on CPG areas of both the JOSPT and the Orthopaedic Section, APTA websites, which are free-access website areas, and submitted to be available free access on the Agency for Healthcare Research and Quality's website (www.guideline.gov). The implementation tools planned to be available for patients, clinicians, educators, payers, policy makers, and researchers, and the associated implementation strategies, are listed in **TABLE 1**.

TABLE 1

PLANNED STRATEGIES AND TOOLS TO SUPPORT THE DISSEMINATION AND IMPLEMENTATION OF THIS CLINICAL PRACTICE GUIDELINE

Tool	Strategy
"Perspectives for Patients"	Patient-oriented guideline summary available on www.jospt.org and www.orthopt.org
Mobile app of guideline-based exercises for patients/clients and health care practitioners	Marketing and distribution of app using www.orthopt.org
Clinician's quick-reference guide	Summary of guideline recommendations available on www.orthopt.org
Read-for-credit continuing education units	Continuing education units available for physical therapists and athletic trainers through JOSPT
Educational webinars for health care practitioners	Guideline-based instruction available for practitioners on www.orthopt.org
Mobile and web-based app of guideline for training of health care practitioners	Marketing and distribution of app using www.orthopt.org
Physical Therapy National Outcomes Data Registry	Support the ongoing usage of data registry for common musculoskeletal conditions of the foot and ankle region
Logical Observation Identifiers Names and Codes mapping	Publication of minimal data sets and their corresponding Logical Observation Identifiers Names and Codes for the foot and ankle region on www.orthopt.org
Non-English versions of the guidelines and guideline implementation tools	Development and distribution of translated guidelines and tools to JOSPT's international partners and global audience via www.jospt.org

Methods *(continued)*

CLASSIFICATION

The terminology used to describe Achilles tendon disorders varies, with “tendinitis,” “tendonitis,” or “paratenonitis” commonly being used and therefore suggestive of an inflammatory condition. Because inflammation and degeneration are usually not mutually exclusive,^{99,111,119,150,152} “midportion Achilles tendinopathy” will be the focus of this clinical guideline unless otherwise stated.

The International Classification of Diseases (ICD-10) code associated with Achilles tendinopathy is **M76.6 Achilles tendinitis/Achilles bursitis**. The corresponding primary ICD-9-CM code, commonly used in the United States, is **726.71 Achilles bursitis or tendinitis**.

The primary ICF body function codes associated with Achilles tendinopathy are **b28015 Pain in lower limb**, **b7300 Power of isolated muscles and muscle groups**, and **b7800 Sensation of muscle stiffness**.

The primary ICF body structures codes associated with Achilles tendinopathy are **s75012 Muscles of lower leg** and **s75028 Structure of ankle and foot, specified as Achilles tendon**.

The primary ICF activities and participation codes associated with Achilles tendinopathy are **d4500 Walking short distances**, **d4501 Walking long distances**, **d4552 Running**, **d4553 Jumping**, and **d9201 Sports**.

A comprehensive list of codes was published in the previous guideline.²²

ORGANIZATION OF THE GUIDELINE

For each topic, the summary recommendation and grade of evidence from the 2010 guideline are presented, followed by a synthesis of the recent literature with the corresponding evidence levels. Each topic concludes with the 2018 summary recommendation and its updated grade of evidence.

CLINICAL GUIDELINES

Impairment/Function-Based Diagnosis

PREVALENCE

2010 Summary

Disorders of the Achilles tendon rank among the most frequently reported overuse injuries in the literature.^{30,116,128,130} The majority of those suffering from Achilles tendinopathy are active individuals, often involved in recreational or competitive sports.¹¹⁴ Estimates of the annual incidence of Achilles tendinopathy in runners range between 7% and 9%.^{101,114} However, cases have been reported in sedentary groups as well.^{92,164} Although runners appear to be the most commonly affected cohort,^{114,116,118,145} Achilles disorders have been reported in a wide variety of sports.^{64,68,114,116,207} Athletes are more likely to become symptomatic when training as opposed to during competitive events.^{101,207} While there is an increased prevalence of Achilles injury as age increases,^{64,113} the mean age of those affected by Achilles disorders is between 30 and 50 years.^{130,148,167} While sex has not been directly studied, data from multiple works suggest that males are affected to a greater extent than females.^{116,145,167}

Evidence Update

I The prevalence of Achilles tendinopathy in elite male soccer players during 1 season ranged from 2.1% to 5.1%.⁷⁶

I In a large prospective cohort of novice runners, 7% went on to develop Achilles tendinopathy.¹⁴⁰

II A systematic review by Sobhani et al¹⁸³ found Achilles tendinopathy to be one of the most common overuse foot and ankle injuries in sports. In a separate systematic review, the reported prevalence of Achilles tendinopathy in the general running and ultramarathon populations ranged from 6.2% to 9.5% and 2.0% to 18.5%, respectively.¹²²

II Achilles tendinopathy was diagnosed in 1.8% of adolescent athletes at a pre-sports participation annual health examination.²³

II The incidence of Achilles tendinopathy was found to be 1.85 per 1000 patients⁴³ and 2.16 per 1000 person-years³ in Dutch general practice populations.

II A review of more than 20 million patient records found that individuals between 40 and 59 years of age were most commonly diagnosed as having Achilles tendinopathy, with a significantly higher incidence than that seen in those between 20 and 39 and between 60 and 69 years of age. No difference in the incidence of Achilles tendinopathy was found between males and females.²¹¹

III Achilles tendinopathy was found to occur in 12.5% of rock climbers.¹⁹

2018 Summary

Midportion Achilles tendinopathy continues to be a relatively common overuse lower extremity soft tissue injury for individuals who are active and participate in sports.

PATHOANATOMICAL FEATURES

2018 Summary and Update

The major complaint of those with midportion Achilles tendinopathy is pain that limits activity. Pain is preceded by an excessive mechanical stressor, such as tensile loading and/or shearing, which initiates pathological changes in the tendon.^{123,129} These pathological changes can include tenocyte proliferation with tendon thickening,^{12,23,55} neovascularity,^{44,151} collagen fibril thinning and disorganization,¹²⁹ increase of non-collagenic and fibrocartilage matrix,^{20,47} fat deposition,^{67,73,78,91} altered fluid movement,⁸⁴ and overproduction of nitric acid with tissue apoptosis.¹⁴⁶ Failure to control hyperthermia that results during exercise, as tendons convert some of the stored energy to heat, can also contribute by causing local cell death.¹²⁹ Tendon changes associated with the pathological process weaken the mechanical and material properties of the tendon. These changes lead to a decrease in tendon stiffness and strength,^{8,9,83,84} ineffective force transfer,^{28,96,141} thereby affecting central nervous system motor control.²⁵ This may provide a rationale for the use of mechanical loading to potentially increase tendon stiffness. Inflammation and degeneration are usually not mutually exclusive but can coexist to a varying extent throughout this process.^{35,99,111,119,150,152}

The extent and/or severity of tendon abnormalities are not consistently related to the severity of clinical presen-

tation.^{31,33,42,44,45,48,54,56,63,79,84} Also, presymptomatic tendon thickening has been documented,^{31,100} and bilateral tendon changes have been found in those with unilateral symptoms.^{56,84} The plantaris tendon may be involved in those with chronic Achilles tendinopathy.^{21,129,142,154,185} The plantaris tendon and associated peritendinous nerve structures may cause impingement on the medial aspect of the thickened Achilles tendon, contributing to pain and activity limitations.^{129,185,186}

Systematic reviews have identified genetic variants as important factors in the pathogenesis of tendinopathy.^{37,129} An abnormal neuronal phenotype can disrupt normal tendon homeostasis and healing after injury.³⁷ The neuronal response to tendon injury involves nerve ingrowth, increased sensitivity to neuronal pain mediators, and receptor activation for these mediators.^{15,29,37,82,100} Neuronal changes activate the nociceptive pathways to higher centers and are responsible for the perception of pain. Therefore, altered central nervous system pain processing may also be an important factor in persistent tendon pain.^{38,89,98,182,195} However, a recent study found that those with Achilles tendinopathy did not display significant features of central sensitization.¹⁵³ Genetic variants, such as those associated with mRNA stability, can predispose individuals to abnormalities in collagen production.^{2,46,62,75,88,155,171,173,179,180} This abnormal collagen may negatively affect the mechanical and material properties of the tendon, leading to ineffective force transfer.^{46,61,155} The relationship between genotype, abnormal collagen, mechanical stress, and symptom presentation is multifactorial and not well understood.^{11,72,156,163,172}

RISK FACTORS

2010 Summary

For specific groups of individuals, clinicians should consider abnormal ankle dorsiflexion range of motion, abnormal subtalar joint range of motion, decreased ankle plantar flexion strength, increased foot pronation, and abnormal tendon structure as intrinsic risk factors associated with Achilles tendinopathy. Obesity, hypertension, hyperlipidemia, and diabetes are medical conditions associated with Achilles tendinopathy. Clinicians should also consider training errors, environmental factors, and faulty equipment as extrinsic risk factors associated with Achilles tendinopathy.

Evidence Update

I A systematic review by Dowling et al⁵⁸ investigating dynamic foot function as a risk factor for lower-limb overuse injuries included only 1 study related to Achilles tendinopathy. This prospective study found altered posterior/anterior force displacement and an increase in laterally directed force distribution underneath the forefoot as risk factors for developing Achilles tendinopathy in runners who

were noted to be “heel-strikers.”²⁰⁰ A prospective cohort study not included in this review found that runners who displayed more medial pressure during stance phase were at risk for injury.¹⁸

II

Franceschi et al⁶⁹ identified obesity as a risk factor for developing tendinopathies in their systematic review.

II

A systematic review by McAuliffe et al¹³⁴ found that tendon abnormalities visualized using ultrasound imaging in asymptomatic tendons were predictive of future tendinopathy. Specifically, in athletes, increased tendon thickness¹⁰⁰ and sonographic abnormalities (moderate or severe hypoechoic defects)³¹ were identified as risk factors for the development of Achilles tendinopathy.

II

A retrospective study investigated injuries in military recruits who were given either a rigid (n = 1416) or shock-absorbing (n = 1338) insole when issued combat boots. The recruits issued a shock-absorbing insole had a 50% reduction in Achilles tendinopathy rate, with an incidence of 4% compared to 8% with the rigid insoles.⁹³

III

A systematic review identified intrinsic risk factors for Achilles tendinopathy to include increasing age, male sex, increased body weight, poor tendon temperature regulation, presence of systemic diseases, decreased muscle strength, decreased flexibility, previous injuries, poor blood supply, and genetic variants.¹²⁹ One study in this review found those with a family history of tendinopathy to have 5 times the risk of developing Achilles tendinopathy.¹¹⁰

III

Systematic reviews found that gene variants influenced the development of Achilles tendinopathy.^{108,202} Specifically, genes associated with the collagen-production pathway may functionally affect tendon strength and stiffness, leading to an abnormal tendon response to loading. This was supported by other studies not included in this review.^{75,157}

III

A systematic review by Lorimer and Hume¹²³ found a posterior-directed center of force when landing, combined with reduced eccentric strength, as potential risk factors for Achilles injury, while having a high arch and generating high propulsion forces were found to be protective against injury.

III

Reviews have noted limited evidence for hip muscle performance as risk factors when generally looking at leg, ankle, and foot injuries.^{138,188} However, another review by Semciw et al¹⁷⁷ found neuromuscular deficits

in gluteus medius function in those with Achilles tendinopathy. A study not included in this review found weakness in the hip abductors, external rotators, and extensors bilaterally in recreational male athletes with chronic midportion Achilles tendinopathy.⁸⁶ Other studies have specifically identified neuromuscular deficits in the gluteus maximus,⁷⁰ rectus femoris,²¹⁴ tibialis anterior,²¹⁴ lateral gastrocnemius,²¹⁴ and triceps surae muscle complex²⁰⁴; altered hip, knee, and ankle moments¹⁰⁵; altered hip biomechanics³⁴; increased lower-limb stiffness³⁹; balance deficits¹⁷⁵; and abnormal lower extremity kinematics during dancing push-off maneuvers¹¹⁵ as intrinsic risk factors.

III In a sample of 24 elite, female soccer players, a sport-specific proprioception training program performed over a 2.5-year duration decreased the rate of Achilles tendinopathy and days lost from play due to injury.¹⁰⁹

III One study in the review by Franceschi et al⁶⁹ identified a potential interaction between age and obesity with degenerative tendon changes.¹⁷⁶ Those with dyslipidemia and fat deposition in the Achilles tendon may be at risk for developing tendon pain.⁷³ This finding is consistent with a systematic review that found that elevated adiposity was frequently associated with general tendon injuries.⁷⁴

III A study of master track-and-field athletes did not find any influence of age, sex, weight, height, or participation in high- versus low-impact activities on the development of Achilles tendinopathy.¹²¹ However, elderly individuals with diabetes who participated in sports were found to be at increased risk for Achilles tendinopathy.¹

III The review by Magnan et al¹²⁹ also identified extrinsic factors in the development of Achilles tendinopathy to include environmental conditions, shoes, equipment, surfaces, and physical activity/sport participation. One study of professional ballet dancers noted overuse injuries to be more common in females and in more technically demanding ballet techniques.¹⁸⁴

III Systematic reviews have specifically identified an increased risk of tendon injury with use of fluoroquinolone antibiotic therapy.^{117,120,129,189}

IV A study included in above reviews found mitochondrial damage to tenocytes during fluoroquinolone treatment to be potentially involved in tendon pathology.¹²⁴

2018 Summary

The risk of developing midportion Achilles tendinopathy is multifactorial and likely related to an interaction of intrinsic

and extrinsic factors that lead to tendon overloading. The body's response to loading will be influenced by health conditions, drugs, and genetic factors. Consequently, many studies of eccentric loading have excluded patients with presumed tissue frailty (TABLE 2). While these conditions are believed to increase risk during eccentric activity, the interactions between physical loads and tendon symptoms are poorly understood for these patients. Clinicians should consider these risk factors in the patient's differential diagnosis.

TABLE 2

SUMMARY OF EXCLUSION CRITERIA FROM STUDIES OF ECCENTRIC EXERCISES DUE TO PRESUMED FRAILTY OF THE PLANTAR FLEXOR MECHANISM AND LOCAL AREA

Exclusion	Example
Surgery	Tendon rupture repair
Connective tissue diseases	
Systemic diseases/disorders	Rheumatic diseases, diabetes
Genetic diseases	Marfan's syndrome
Medications	Local steroid injection, systemic fluoroquinolones
Pregnancy	
Age	Youths and adolescents
Fracture	
Other local disease states	Peripheral vascular disease

An individual with any number of lower extremity impairments that lead to abnormal kinetics and/or kinematics that specifically produce an eccentric overload of the Achilles tendon may be at risk for Achilles tendon injury. The use of shock-absorbing insoles may help prevent midportion Achilles tendinopathy.

CLINICAL COURSE

2010 Summary

No summary.

Evidence Update

I In elite male soccer players, missed participation because of symptoms related to Achilles tendinopathy was relatively brief (median, 10 days; average, 23 days). However, recurrence rate was high (27%), with a greater risk of reinjury for players resting less than 10 days. In those with severe tendinopathies (more than 28 days lost), 38% required surgical intervention.⁷⁶

I In a large prospective cohort of runners, the median time to recovery was 82 days (minimum, 21; maximum, 479).¹⁴⁰

II The lack of uniformity in Achilles tendon structure on ultrasonography (hyperechogenicity/hypoecho-genicity) is not a consistent predictor for outcome.^{12,42}

II Sex may influence response to treatment with eccentric exercise, as females with Achilles tendinopathy perceived more pain and less of an improvement in function compared to males following 12 weeks of eccentric training.¹⁰⁷

II Good long-term outcomes were noted in 4.2-year⁷⁹ and 5-year¹⁹⁹ follow-up studies of individuals who completed a 3-month heavy-load eccentric calf muscle training program. However, mild pain persisted in some individuals,¹⁹⁹ and there was considerable variability in treatment outcomes.^{71,130,168}

III A study of National Basketball Association players found that there was an association between Achilles tendinopathy and a decline in performance, with younger players having a better chance of returning to competition.⁶

III Conflicting evidence related to body mass index (BMI) was identified. The systematic review by Franceschi et al⁶⁹ found that greater BMI played a role in the development of Achilles tendinopathy. However, a study in this review revealed that BMI did not influence response to nonsurgical treatment.¹⁰⁶

IV A case series by Silbernagel et al¹⁸² found that 80% (27/34) of participants who completed a 12-week to 6-month progressive Achilles tendon-loading strengthening program were fully recovered at 5-year follow-up.

2018 Summary

In athletes with midportion Achilles tendinopathy, missed participation can be expected to be brief. However, a decline in performance may occur in older athletes, and symptoms may return if not properly treated immediately after injury. Recovery time can vary from brief to many months and is probably dependent on the severity of the injury. Recovery may be influenced by intrinsic factors, such as sex. While most patients will improve, mixed levels of recovery can be anticipated.

DIAGNOSIS/CLASSIFICATION

2010 Recommendation

C Self-reported localized pain and perceived stiffness in the Achilles tendon following a period of inactivity (eg, sleep, prolonged sitting) lessen

with an acute bout of activity and may increase after the activity. Symptoms are frequently accompanied by Achilles tendon tenderness, a positive arc sign, and positive findings on the Royal London Hospital test. These signs and symptoms are useful clinical findings for classifying a patient with ankle pain into the ICD category of Achilles bursitis or tendinitis and the associated ICF impairment-based category of Achilles pain (**b28015 Pain in lower limb**), stiffness (**b7800 Sensation of muscle stiffness**), and muscle power deficits (**b7301 Power of muscles of lower limb**).

Evidence Update

II Hutchison et al⁹⁴ examined 21 participants with and without Achilles tendinopathy who underwent an ultrasound scan followed by 10 clinical tests for midportion Achilles tendinopathy. Subjective reporting of pain 2 to 6 cm proximal to the Achilles insertion, extending to the calcaneus (sensitivity, 84%; specificity, 73%; $\kappa = 0.74-0.96$), and pain with palpation of the midportion of the tendon (sensitivity, 78%; specificity, 77%; $\kappa = 0.75-0.81$) was found to be accurate and reliable in diagnosing midportion Achilles tendinopathy.

III Reiman and colleagues¹⁶⁰ performed a systematic review and meta-analysis of the utility of current clinical measures for the diagnosis of Achilles tendon injuries. Because only 2 studies met the inclusion criteria, the authors determined that further high-quality studies are needed.

2018 Recommendation

C In addition to the arc sign and Royal London Hospital test,¹²⁷ clinicians can use a subjective report of pain located 2 to 6 cm proximal to the Achilles tendon insertion that began gradually and pain with palpation of the midportion of the tendon to diagnose midportion Achilles tendinopathy.

DIFFERENTIAL DIAGNOSIS

2010 Recommendation

See slightly modified recommendation below.

Evidence Update

IV Using ultrasound scans in patients with pain in the Achilles tendon region, Morton and colleagues¹³⁷ identified tears in fascial tissue that divide the leg into its compartments.

IV The plantaris tendon may play a role in chronic midportion Achilles regional pain. A recent retrospective study examined the incidence of plantaris

injuries in track-and-field athletes and found that plantaris injury occurred with an annual incidence of 3.9% to 9.3%.¹⁵⁴

V Dalbeth and colleagues³⁶ reported on the frequency and patterns of monosodium urate (MSU) crystal deposition in tendons and ligaments of patients with gout using dual-energy computed tomography (DECT). Ninety-two people with tophaceous gout had DECT scanning of both feet, with the Achilles tendon being the most common site of MSU crystal deposition.

2010 and 2018 Summary

Clinicians should consider diagnostic classifications other than midportion Achilles tendinopathy, including involvement of the plantaris tendon,¹⁵⁴ when the patient's reported activity limitations or impairments of body function and structure are not consistent with those presented in the Diagnosis, Classification, and Clinical Course sections of this updated guideline, or when the patient's symptoms are not resolving with interventions aimed at normalization of the patient's impairments of body function.

The following conditions should be considered in the differential diagnosis of patients presenting with posterior ankle pain:

- Acute Achilles tendon rupture^{4,166}
- Partial tear of the Achilles tendon^{24,104}
- Retrocalcaneal bursitis¹⁰²
- Posterior ankle impingement¹⁷⁰
- Irritation or neuroma of the sural nerve⁴
- Os trigonum syndrome¹³²
- Accessory soleus muscle¹²⁵
- Achilles tendon ossification¹⁶¹
- Systemic inflammatory disease⁵
- Plantaris tendon involvement¹⁵⁴
- Fascial tears¹³⁷
- Insertional Achilles tendinopathy

IMAGING

2010 Summary

When a diagnosis of Achilles tendinopathy is not clear from the history and physical examination, imaging studies are warranted. Ultrasound and magnetic resonance imaging (MRI) are of assistance when clinical exam results are not sufficient to arrive at a diagnosis.

2018 Update and Summary

Ultrasound imaging and MRI may be useful in assessing for differential diagnoses and identifying coexisting pathology, such as partial ruptures, bursitis, paratendonitis, plantaris involvement, and/or fascial tears.^{53,60,133,137} Research studies on patients with midportion Achilles tendinopathy commonly use imaging techniques to examine the severity of ten-

dinopathy, with signs including increased tendon thickness (eg, anterior/posterior diameter or cross-sectional area), altered composition (eg, echogenicity on ultrasound and signal intensity on MRI), and/or neovascularization (eg, location and extent of activity on Doppler ultrasound).^{9,78,143,151,191,201,208} However, there is conflicting evidence on the level of association between severity of tendon abnormalities and symptoms.^{12,16,42,44,51,56,63,67,80,85,143,144,162,178,187,193,201,209,210} There are techniques currently being developed using ultrasound elastography to estimate tissue mechanical properties (eg, strain and stiffness), which may provide greater insight into tendon pathology in the future.^{77,90}

Decision Tree Model

A pathoanatomical/medical diagnosis of midportion Achilles tendinopathy can provide valuable information in describing tissue pathology and may assist in planning treatment and predicting prognosis. The proposed model for examination, diagnosis, and treatment planning for patients with Achilles pain, stiffness, and muscle power deficits associated with midportion Achilles tendinopathy uses the following components: (1) medical screening, (2) classification of the condition through evaluation of clinical findings suggestive of musculoskeletal impairments of body functioning (ICF) and associated tissue pathology/disease (ICD), (3) determination of irritability stage, (4) determination of evaluative outcome measures, and (5) intervention strategies for patients in acute and nonacute stages. This model is depicted in the **FIGURE**.

Component 1

Medical screening incorporates the findings from the history and physical examination to determine whether the patient's symptoms originate from a condition that requires referral to another health care provider. Acute Achilles tendon rupture and systemic inflammatory disease would be examples of conditions that would require referral to another health care provider.

Component 2

Evaluation of physical examination findings, as outlined in the **FIGURE**, should be consistent with the diagnosis of midportion Achilles tendinopathy. The diagnosis and management of the patient's condition should be appropriately modified if the evaluation of clinical findings related to the musculoskeletal impairments of body functioning (ICF) and associated tissue pathology/disease (ICD) suggest other foot or ankle conditions in a differential diagnosis list, symptoms from the lumbopelvic region, or systemic or medical disease.

Component 3

Irritability is a term used by rehabilitation practitioners to reflect the tissue's ability to handle physical stress,¹³⁵ and is

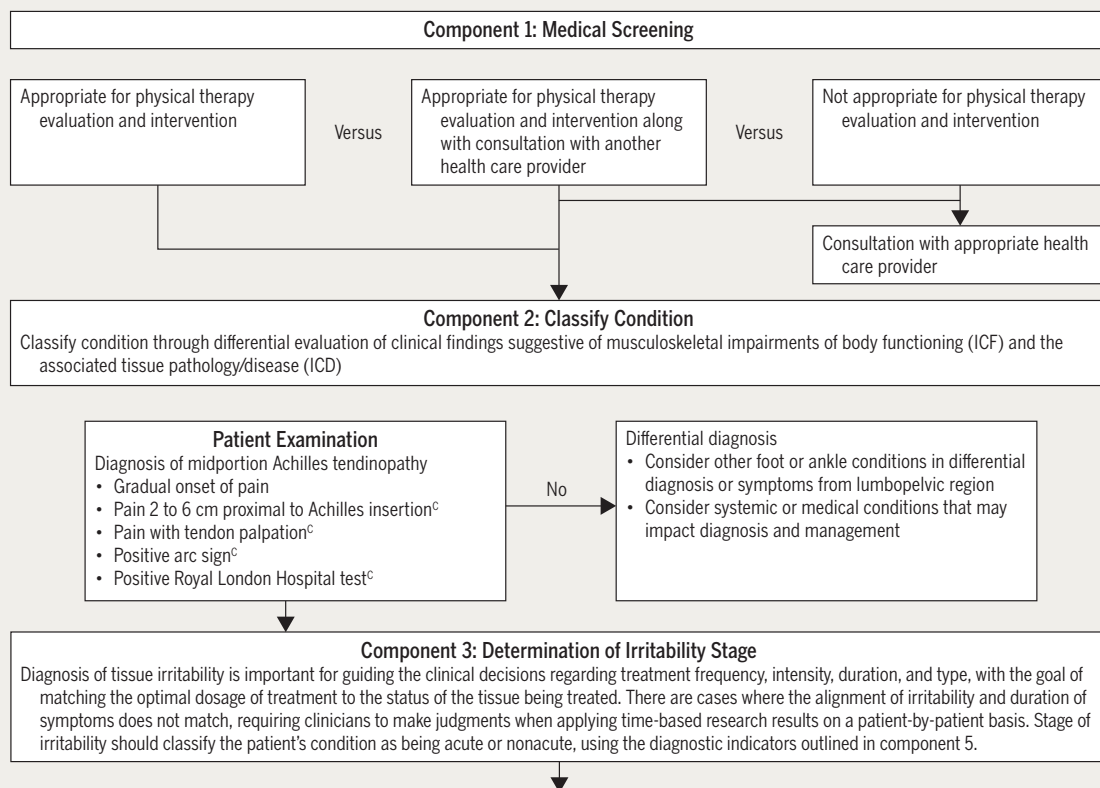


Figure continues on page A13.

FIGURE. Model of diagnosis, examination, and treatment of Achilles pain, stiffness, and muscle power deficits. Superscript letters indicate that the guidelines are based on (A) strong evidence, (B) moderate evidence, (C) weak evidence, (D) conflicting evidence, (E) theoretical/foundational evidence, or (F) expert opinion.

presumably related to physical status and the extent of injury and inflammatory activity that is present. Diagnosis of tissue irritability as acute or nonacute, according to the signs, symptoms, and duration of the condition, is important in guiding the clinical decisions regarding the intervention strategies as outlined in component 5.

Component 4

Outcome measures include an assessment of the patient's functional level and associated physical impairments as outlined in the **FIGURE**. Standardized tools, such as the VISA-A, FAAM, and LEFS, can be used for measuring a specific domain, whether it is a body structure or function, activity limitation, or participation restriction. Outcome measures are important in direct management of individual patient care, and they provide the opportunity to collectively compare care and determine effectiveness through the repeated application of standardized measurement.

Component 5

Intervention strategies outline criteria for treatment selection based on diagnostic indicators and clinical examina-

tion findings and allow for treatment planning based on re-evaluation. Interventions are grouped based on the following categories: therapeutic exercise (exercise, stretching, neuromuscular education), manual therapy, education (patient education, patient counseling), home use of medical supplies (bracing), and clinical use of medical devices (iontophoresis). A higher level of evidence indicates greater scientific support for the recommendation, not necessarily the intervention itself. For example, there is a relatively high-level of evidence for the recommendation *not* to use night splints for patients with midportion Achilles tendinopathy. Interventions outside of the scope of physical therapy, including corticosteroid injection, extracorporeal shockwave therapy (ESWT), and platelet-rich plasma (PRP) injections, are included as education for patients who are seeking additional treatment options. Of note, the majority of studies include patients with chronic midportion Achilles tendinopathy. Therefore, treatment of a patient with acute Achilles tendinopathy may depend more on clinical judgment and expert opinion.

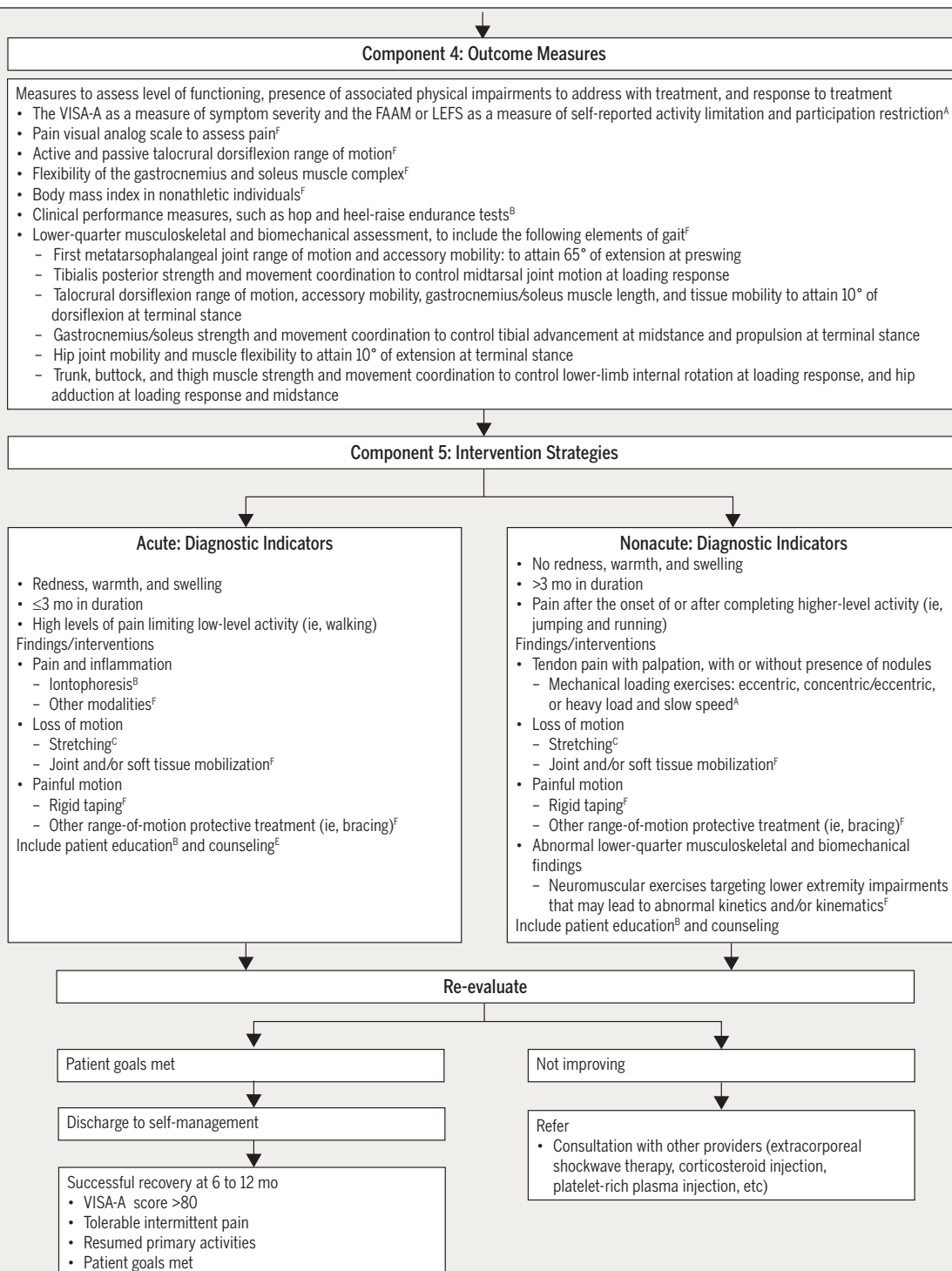


FIGURE (CONTINUED). Model of diagnosis, examination, and treatment of Achilles pain, stiffness, and muscle power deficits. Superscript letters indicate that the guidelines are based on (A) strong evidence, (B) moderate evidence, (C) weak evidence, (D) conflicting evidence, (E) theoretical/foundational evidence, or (F) expert opinion.

CLINICAL GUIDELINES

Examination

OUTCOME MEASURES – ACTIVITY LIMITATIONS/ SELF-REPORTED MEASURES

2010 Recommendation

A Clinicians should incorporate validated functional outcome measures, such as the Victorian Institute of Sport Assessment-Achilles (VISA-A) and the Foot and Ankle Ability Measure (FAAM). These should be utilized before and after interventions intended to alleviate the impairments of body function and structure, activity limitations, and participation restrictions associated with Achilles tendinopathy.

Evidence Update

I Iversen et al⁹⁷ provided evidence of validity and reliability for the VISA-A questionnaire in Danish-speaking individuals.

II The VISA-A has been validated for patients with Achilles tendinopathy who speak Turkish⁵⁷ and French.¹⁰³ The validity and reliability findings in these studies are consistent with the results reported in the previously published Achilles tendinopathy guideline.²²

II Systematic reviews have assessed the evidence to support outcome measures for those with lower-leg, ankle, and foot conditions.^{136,181} The Lower Extremity Functional Scale (LEFS) and FAAM were found to be most commonly used, with the FAAM receiving the highest quality assessment score for responsiveness.¹⁸¹ A separate systematic review found evidence of reliability, validity, and responsiveness to support the LEFS for individuals with lower-limb musculoskeletal conditions.¹³⁶

2018 Recommendation

A Clinicians should use the VISA-A to assess pain and stiffness, and either the FAAM or the LEFS to assess activity and participation in patients with a diagnosis of midportion Achilles tendinopathy.

ACTIVITY LIMITATIONS/PHYSICAL PERFORMANCE MEASURES

2010 Recommendation

B When evaluating functional limitations over an episode of care for those with Achilles tendinopathy, measures of activity limitation and participation restriction can include objective and reproducible assessment of the ability to walk, descend stairs, perform unilateral heel raises, single-limb hop, and participate in recreational activity.

Evidence Update

V A review by MacDermid and Silbernagel¹²⁶ summarized physical performance measures for selected upper and lower extremity tendinopathies. They recommended the hop tests and the heel-raise endurance test in the evaluation of functional performance in patients with Achilles tendinopathy.

2018 Recommendation

B Clinicians should use physical performance measures, including hop and heel-raise endurance tests as appropriate, to assess a patient's functional status and document findings.

PHYSICAL IMPAIRMENT MEASURES

Recommended impairment measures and their properties are provided in the 2010 CPG.²² See the **FIGURE** in the 2010 CPG for the summary of recommended physical impairment measures.

2010 and 2018 Recommendation

B When evaluating physical impairment over an episode of care for those with Achilles tendinopathy, one should measure ankle dorsiflexion range of motion, subtalar joint range of motion, plantar flexion strength and endurance, static arch height, forefoot alignment, and pain with palpation.

CLINICAL GUIDELINES

Interventions

A systematic search of the literature did not reveal articles to alter the 2010 recommendations for iontophoresis, manual therapy, or heel lifts in the treatment of midportion Achilles tendinopathy. Updated recommendations are provided for exercise, which includes eccentric, eccentric/concentric, and heavy-load, slow-speed protocols; stretching; night splints; low-level laser therapy (LLLT); orthoses; taping; neuromuscular re-education; and dry needling. Although corticosteroid injection, ESWT, and PRP injections are used as interventions for those with Achilles tendinopathy, they are outside the scope of physical therapy practice, and therefore only summaries are provided for patient education purposes.

EXERCISE

2010 Recommendation

A Clinicians should consider implementing an eccentric loading program to decrease pain and improve function in patients with midportion Achilles tendinopathy.

Evidence Update

I In a systematic review by Sussmilch-Leitch et al,¹⁹² 9 randomized controlled trials, all published before 2009, directly studied eccentric exercise. This systematic review supported the use of eccentric exercise for midportion Achilles tendinopathy.

I Beyer et al¹⁴ found similar outcomes for a heavy-load, slow-speed exercise and an eccentric training protocol. The heavy-load, slow-speed exercise protocol included 3 bilateral full-range-of-motion heel-raise exercises performed at a speed of 6 seconds per repetition as follows: (1) flexed knee on a seated calf-raise machine, (2) extended knee with the barbell on shoulders, and (3) extended knee on a leg-press machine. The 12-week program included increasing weight with progressively decreasing repetitions. The dosages per week were as follows: week 1, 3 sets of 15 repetitions; weeks 2 and 3, 3 sets of 12 repetitions; weeks 4 and 5, 4 sets of 10 repetitions; weeks 6 to 8, 4 sets of 8 repetitions; and weeks 9 to 12, 4 sets of 6 repetitions. Notable findings at 52-week follow-up included lower visual analog scale (VAS) pain scores during running in both groups (mean VAS change from 0 to 52 weeks: eccentric training group, -38 [95% confidence interval (CI)]: -49.9, -25.6; heavy, slow resistance group, -49 [-62.8, -35.5]), lower VISA-A in both groups (mean VISA-A change from 0 to 52 weeks: eccentric

training group, -27.0 [-35.6, -18.0]; heavy, slow resistance group, -34.0 [-41.8, -26.5]), decreased anterior-to-posterior tendon width, and decreased Doppler signal. Although at 52 weeks patients in both groups continued to have pain with running (mean VAS running: eccentric exercise group, 12 [95% CI: 3.2, 19.8]; heavy, slow resistance group, 5 [-0.5, 9.8]), patients in both groups expressed high levels of satisfaction (eccentric exercise group, 76%; heavy, slow resistance group, 98%).

II Although several systematic reviews supported eccentric exercises, heterogeneity across exercise protocols was identified, including factors such as maximum load, speed of contraction, and frequency of sessions not being adequately controlled.^{71,87,130,168} Malliaras et al¹³¹ noted that trials often did not isolate eccentric from concentric contractions, and therefore questioned the need for an eccentric-only exercise protocol. However, Frizziero et al⁷¹ found eccentric training to be more effective than concentric exercises, general therapeutic exercise, and ESWT. It should be noted that compliance with eccentric training (27%-72%)⁸⁷ and outcomes were found to vary considerably across studies.^{71,87,130,168}

II A randomized controlled trial (n = 80, 20 per group) examined daily eccentric exercise (twice per day, 7 days per week) compared to twice weekly eccentric exercise (once per day, twice per week).¹⁹⁶ At 12 weeks, the differences in the VISA-A score between the daily exercise and twice-weekly eccentric exercise groups were not significant.

II Stevens and Tan¹⁹⁰ compared 2 intensities of the Alfredson eccentric protocol in a small sample (13-15 per group) of patients. Those in the "do as tolerated" group completed an average of 112 repetitions daily, while those in the "protocol" group averaged 166 repetitions. No significant differences between groups were found on pain VAS or VISA-A scores at 6 weeks.

IV The case series study by Ram et al¹⁵⁸ evaluated the responses of 16 of 20 participants with chronic midportion Achilles tendinopathy who had tried at least 1 other treatment to a 12-week eccentric training program. Despite experiencing improved scores on the VISA-A, pain VAS, and Tegner activity scale, only 2 participants were satisfied with treatment. Compared to other studies, the low satisfaction may have to do with the fact that patients had a chronic condition and had tried other treatments.¹⁴

IV

de Vos et al⁴⁸ examined changes in tendon structure using a specific ultrasonic tissue characterization approach before and after a 16-week eccentric exercise program. The changes defined by the ultrasonic tissue characterization approach found no association between collagen type and VISA-A scores at any time point.

IV

Several randomized controlled trials compared eccentric exercise combined with other interventions to eccentric exercise alone.^{41,49,50,147,165,196,197,212,215}

The observed changes in the control groups (eccentric exercise alone) provide useful information. Improvement in symptom severity (VISA-A) across studies varied in these control groups from 2.4% at 8 weeks,²¹⁵ 13% at 12 weeks,¹⁴⁷ 22.6% at 16 weeks,¹⁶⁵ 20.5% at 24 weeks,⁵⁰ to 25% to 30% at 52 weeks.^{41,197} When eccentric exercise was combined with PRP,^{41,49,50} autologous blood injections,¹⁴⁷ or prolotherapy,²¹² the results were equivalent to eccentric exercise alone. However, when eccentric exercise was combined with LLLT,¹⁹⁶ ESWT,¹⁶⁵ or acupuncture,²¹⁵ studies favored the combined treatments.

It should be noted that studies have excluded participants with presumed frailty of the tendon structure because of metabolic or genetic diseases and drugs. Therefore, little is known about risks and benefits of eccentric exercise for these patients.

Because specific factors (eg, frequency, load, and speed) are not standardized across studies, the optimum parameters for exercise are yet to be formulated.

2018 Recommendation

A

Clinicians should use mechanical loading, which can be either in the form of eccentric or a heavy-load, slow-speed (concentric/eccentric) exercise program, to decrease pain and improve function for patients with midportion Achilles tendinopathy without presumed frailty of the tendon structure.

F

Patients should exercise at least twice weekly within their pain tolerance.

STRETCHING

2010 Recommendation

C

Clinicians may use plantar flexor stretching with the knee flexed and extended to reduce pain and improve satisfaction with outcome in patients with midportion Achilles tendinopathy who exhibit limited dorsiflexion range of motion.

Evidence Update

IV

A study by Verrall et al²⁰³ evaluated a single cohort of patients performing a 6-week stretching program that was described as an “eccentric stretching” protocol. One set required participants to perform 9 plantar flexor stretches (6 with knee straight and 3 with knee bent) off the end of a step. Each “heel drop” stretch was held for 15 to 20 seconds. Participants increased from 1 set to 3 and from bilateral to the involved side over a 6-week period. Pain decreased on a 0-to-10 VAS scale from 7.2 at baseline to 2.9 at 12 weeks. Eighty-two percent of participants reported a level of satisfaction of 7/10 or greater with treatment.

2018 Recommendation

C

Clinicians may use stretching of the ankle plantar flexors with the knee flexed and extended to reduce pain and improve satisfaction with outcome in patients with midportion Achilles tendinopathy who exhibit limited ankle dorsiflexion range of motion.

NEUROMUSCULAR RE-EDUCATION

2010 Recommendation

No recommendation.

Evidence Update

IV

Neuromuscular control among runners with midportion Achilles tendinopathy has been examined in several case-control studies.^{10,13,70} Running studies identified patterns of decreased lower extremity muscle activity in participants with midportion Achilles tendinopathy compared to a control group.^{10,13,70} However, it is unclear whether decreased muscle activity is a cause or a result of midportion Achilles tendinopathy, and whether an intervention targeting these altered patterns of muscle activity improve outcomes.

2018 Recommendation

F

Clinicians may use neuromuscular exercises targeting lower extremity impairments that may lead to abnormal kinetics and/or kinematics, specifically eccentric overload of the Achilles tendon during weight-bearing activities.

MANUAL THERAPY

2010 Recommendation

F

Clinicians may use joint and soft tissue mobilization to reduce pain and improve mobility and function in patients with midportion Achilles tendinopathy.

Evidence Update

V Cheatham et al²⁷ looked at the efficacy of soft tissue mobilization in a systematic review. Although there were no studies specific to those with midportion Achilles tendinopathy, there appeared to be some evidence supporting instrument-augmented soft tissue mobilization for improving motion in a limited number of studies.

2018 Recommendation

F Clinicians may consider using joint mobilization to improve mobility and function and soft tissue mobilization to increase range of motion for patients with midportion Achilles tendinopathy

PATIENT EDUCATION: ACTIVITY MODIFICATION

2010 Recommendation

No recommendation.

Evidence Update

I Silbernagel et al¹⁸² compared the effects of continued sports activity (eg, running and jumping activities below a specified pain intensity) to active rest while patients completed an exercise program for midportion Achilles tendinopathy. Patients in the active rest group could choose to swim, run in deep water, bike, or walk as a daily activity. The specific guideline was for patients to maintain pain levels below a 5/10 on a VAS for all activities. All participants performed a standardized exercise program. Both groups significantly improved on the VISA-A at 5-year follow-up, with the mean VISA-A scores greater than 90 for both groups.¹⁸²

2018 Recommendation

B For patients with nonacute midportion Achilles tendinopathy, clinicians should advise that complete rest is not indicated and that they should continue with their recreational activity within their pain tolerance while participating in rehabilitation.

PATIENT COUNSELING

2010 Recommendation

No recommendation.

Evidence Update

V There is no direct evidence that patient counseling benefits patients with Achilles tendinopathy. However, patient education and counseling are both considered important for patient care.^{168,182}

2018 Recommendation

E Clinicians may counsel patients with midportion Achilles tendinopathy. Key elements of patient counseling could include (1) theories supporting use of physical therapy and role of mechanical loading; (2) modifiable risk factors, including BMI and footwear; and (3) typical time course for recovery from symptoms.

HEEL LIFTS

2010 and 2018 Recommendation

D Because contradictory evidence exists, no recommendation can be made for the use of heel lifts in patients with midportion Achilles tendinopathy.

NIGHT SPLINTS

2010 Recommendation

C Night splints are not beneficial in reducing pain when compared to eccentric exercise in patients with Achilles tendinopathy.

Evidence Update

I A systematic review by Sussmilch-Leitch et al¹⁹² found 2 studies with conflicting results on the additional effect of night splints added to an eccentric exercise program. A pooled meta-analysis found that a night splint provided no significant additional improvement in patient-reported symptoms (VISA-A) at 12 weeks.

II A 1-year follow-up randomized controlled trial found no additional benefit of a night splint to eccentric exercise.⁴⁰ There were no significant differences in symptom severity (VISA-A) between groups at baseline or 3-month and 1-year follow-ups. There were also no significant differences between groups in morning stiffness or patient satisfaction at 1-year follow-up.

2018 Recommendation

C Clinicians should not use night splints to improve symptoms in patients with midportion Achilles tendinopathy.

ORTHOSSES

2010 Recommendation

C A foot orthosis can be used to reduce pain and alter ankle and foot kinematics while running in patients with Achilles tendinopathy.

Evidence Update

II

Two systematic reviews noted no effect of orthoses for patients with midportion Achilles tendinopathy.^{130,168}

I

Munteanu et al¹³⁹ examined the effects of a custom orthosis compared with a sham orthosis. All participants also performed an eccentric exercise program. No difference was found in VISA-A scores at baseline and at 1, 3, 6, and 12 months between the 2 groups.

2018 Recommendation

D

Because contradictory evidence exists, no recommendation can be made for the use of orthoses in patients with midportion Achilles tendinopathy.

TAPING

2010 Recommendation

F

Taping may be used in an attempt to decrease strain on the Achilles tendon in patients with Achilles tendinopathy.

Evidence Update

IV

A systematic review noted that 1 of 2 low-level studies supported taping for midportion Achilles tendinopathy.¹⁶⁸

IV

A case-control study⁶⁶ examined the immediate effects of therapeutic elastic tape applied to the Achilles tendon and found application of tape did not improve hop distance or decrease pain.

2018 Recommendation

F

Clinicians should not use therapeutic elastic tape to reduce pain or improve functional performance in patients with midportion Achilles tendinopathy.

F

Clinicians may use rigid taping to decrease strain on the Achilles tendon and/or alter foot posture in patients with midportion Achilles tendinopathy.

LOW-LEVEL LASER THERAPY

2010 Recommendation

B

Clinicians should consider the use of LLLT to decrease pain and stiffness in patients with Achilles tendinopathy.

Evidence Update

II

Tumilty and colleagues¹⁹⁷ compared LLLT to placebo laser treatment while both groups concurrently participated in an eccentric exercise program. The laser parameters were set at 810 nm, 100-mW infrared probe, at 3.0 J per point (18 J per session). The LLLT group did not have clinically or statistically greater improvement in the numeric pain-rating scale or symptom severity (VISA-A) at baseline and at 4, 12, and 52 weeks.

II

Hutchison et al⁹⁵ compared LLLT to a placebo laser treatment using a laser probe, with a spectrum of 530 nm to 1100 nm, to administer a single pulse of 39 J. There were no differences between groups in symptom severity (VISA-A), pain (VAS), or function (LEFS) at baseline and at 6 or 12 weeks. In addition, at 12 weeks, neither group demonstrated a significant difference from baseline in patient-reported outcome measures (95% CI of difference from baseline: VISA-A, -7.2, 7.2; VAS, -15.8, 9.6; LEFS, -4.44, 7.33).

II

A randomized trial (n = 80, 20 per group) examined 2 different exercise regimens and the ability of laser to supplement these programs.¹⁹⁶ The 4 arms of the study included placebo plus daily exercise, LLLT plus daily exercise, placebo plus twice-weekly exercise, and LLLT plus twice-weekly exercise. The key significant finding at 12 weeks was that the combination of LLLT plus twice-weekly exercise resulted in the greatest improvement in symptom severity over the 12-week period, as measured by the VISA-A (mean improvement, 18.5% [95% CI: 9.1%, 27.9%]), achieving an average score near the ceiling of the VISA-A (score, 99). In addition, differences between placebo plus daily exercise and LLLT plus daily exercise, although not significant, favored LLLT plus daily exercise by an average of 8.2% (95% CI: -1.3%, 17.7%). Although only the results for LLLT plus twice-weekly exercise were significant, the study was underpowered to determine whether laser was better than no laser. This leaves open the possibility that laser may have significant effects not just for specific exercise protocols but across different exercise protocols.

2018 Recommendation

D

Because contradictory evidence exists, no recommendation can be made for the use of LLLT in patients with midportion Achilles tendinopathy.

IONTOPHORESIS

2010 and 2018 Recommendation

B

Clinicians should use iontophoresis with dexamethasone to decrease pain and improve function in patients with acute midportion Achilles tendinopathy.

DRY NEEDLING**2010 Recommendation**

No recommendation.

Evidence Update

In a recent prospective cohort study,²⁰⁶ comparisons were made between high-volume image-guided injection (HVIGI) with and without dry needling. Participants in the HVIGI-only group improved an average of 33.4 points on the VISA-A, while the participants in the HVIGI and dry needling group on average only improved by 6.9 points.



In a case series study by Yeo et al,²¹³ participants received tendon injection of marcaine (tendon decompression) followed by dry needling in conjunction with a 4-week eccentric exercise program. Pain VAS scores (0-100) during rest and activity decreased by 24% and 39.1%, respectively, at 6 weeks post procedure. At 12 and 24 months, 77% and 76% of participants, respectively, had high or very high satisfaction levels.

2018 Recommendation

Clinicians may use combined therapy of dry needling with injection under ultrasound guidance and eccentric exercise to decrease pain for individuals with symptoms greater than 3 months and increased tendon thickness.

INTERVENTIONS OUTSIDE THE SCOPE OF PHYSICAL THERAPY

Summaries were not provided in 2010 for corticosteroid injection, ESWT, and PRP injections.

CORTICOSTEROID INJECTION**2018 Summary**

A systematic review of randomized controlled trials of corticosteroid injections for all types of tendinopathy concluded that an initial short-term benefit is not maintained at intermediate and long-term follow-up.³² Although the risk of a tendon rupture is low, other minor complications are more common, including postinjection pain, subcutaneous atrophy, and skin depigmentation.³² Patients with Achilles tendinopathy who did not respond to exercises alone received up to 3 glucocorticosteroid injections (76% received at least

1 injection) in this observational study (midportion tendinopathy, n = 75; insertional tendinopathy, n = 18).²⁰⁵ Patients managed with either exercise alone or a combination of exercise and glucocorticosteroid injections had good outcomes in this cohort at 6 months (94% reported improvement and 77% reported an excellent or good result).^{59,205} Similarly, in a recent randomized controlled study and systematic review, participants who received high-volume corticosteroid injections coupled with eccentric exercises demonstrated an improvement of 29 points in their VISA-A at 24 weeks, while those in the exercise-only group improved 11 points.^{17,26}

EXTRACORPOREAL SHOCKWAVE THERAPY**2018 Summary**

Extracorporeal shockwave therapy, when combined with eccentric exercise for chronic midportion Achilles tendinopathy, is supported in some systematic reviews with improvement in VISA-A score, pain, and function.^{71,81,130,168,192} The only systematic review to perform a meta-analysis noted no effect favoring ESWT alone. However, qualitative evidence favors ESWT when combined with eccentric exercise.¹⁹² Two case series also provide low-level evidence in support of the use of ESWT.^{174,194} Saxena et al¹⁷⁴ demonstrated significant improvement with ESWT on a ranking of daily and recreational activities at 1-year follow-up, with a total of 78% of the patients considering themselves improved. Taylor et al¹⁹⁴ studied ESWT in patients with midportion Achilles tendinopathy who did not respond to initial therapy (average length of symptoms of 20 months). At 2-year follow-up, patients demonstrated an improvement in the VISA-A from 40 at baseline to 66.¹⁹⁴ However, there was no difference in pain VAS between baseline and the 2-year follow-up. In summary, there is evidence that ESWT benefits patients with chronic midportion Achilles tendinopathy when combined with eccentric exercise. Evidence supporting ESWT alone and optimal dosage (eg, high versus low energy) is unclear.

PLATELET-RICH PLASMA INJECTION**2018 Summary**

Many systematic reviews determined that high-level evidence does not support the use of PRP injections for a variety of outcomes, including VISA-A, return to sport, ultrasound measures, and function (eg, FAAM), for individuals with midportion Achilles tendinopathy.^{7,52,65,112,159,169,198}

AFFILIATIONS AND CONTACTS

AUTHORS

Christopher R. Carcia, PT, PhD
Associate Professor
Department of Physical Therapy
John G. Rangos, Sr. School of Health
Sciences
Duquesne University
Pittsburgh, PA
carcia@duq.edu

Ruth Chimenti, DPT, PhD
Post Doctoral Fellow
Department of Physical Therapy and
Rehabilitation Science
University of Iowa
Iowa City, IA
ruth-chimenti@uiowa.edu

Tyler Cuddeford, PT, PhD
Program Director
School of Physical Therapy
George Fox University
Newberg, OR
tcuddeford@georgefox.edu

Jeff Houck, PT, PhD
Professor
Director of Research
Physical Therapy Program
George Fox University
Newberg, OR
jhouck@georgefox.edu

Robroy L. Martin, PT, PhD
Professor
John G. Rangos, Sr. School of Health
Sciences
Duquesne University
Pittsburgh, PA
and
Staff Physical Therapist
UPMC Center for Sports Medicine
Pittsburgh, PA

martinr280@duq.edu
J.W. Matheson, DPT
President and Clinic Director
Catalyst Sports Medicine
Hudson, WI
jwmatheson@catalystsportsmedicine.com

Christine M. McDonough, PT, PhD
ICF-Based Clinical Practice Guidelines
Editor
Orthopaedic Section, APTA, Inc
La Crosse, WI
and
Assistant Professor of Physical Therapy
School of Health and Rehabilitation
Sciences
University of Pittsburgh
Pittsburgh, PA
Cmm295@pitt.edu

Stephen Paulseth, DPT, MS
Paulseth & Associates Physical Therapy
Los Angeles, CA
www.paulsethpt.com
and
Adjunct Clinical Instructor
Division of Biokinesiology and Physical
Therapy
University of Southern California
Los Angeles, CA

Dane K. Wukich, MD
Dr Charles F. Gregory Distinguished
Chair of Orthopaedic Surgery
University of Texas Southwestern
Medical Center
Dallas, TX

REVIEWERS

Paul Beattie, PT, PhD
Clinical Professor
Doctoral Program in Physical Therapy,

Department of Exercise Science
Arnold School of Public Health
University of South Carolina
Columbia, SC
pbeattie@mailbox.sc.edu

Yu-Jen Chang, PhD
Assistant Professor
Division of Physical Therapy
School of Medicine
West Virginia University
Morgantown, WV
yujen.chang@hsc.wvu.edu

John DeWitt, DPT
Director of Physical Therapy
Residencies and Fellowships
The Ohio State University
Columbus, OH
john.dewitt@osumc.edu

Amanda Ferland, DPT
Clinical Faculty
Tongji University/USC Division of
Biokinesiology and Physical Therapy
Orthopaedic Physical Therapy
Residency and Spine Rehabilitation
Fellowship
Shanghai, China
AmandaFerland@incarehab.com

Sandra Kaplan, PT, PhD
Clinical Practice Guidelines Coordinator
Academy of Pediatric Physical Therapy,
APTA, Inc
and
Professor
Doctoral Programs in Physical Therapy
Rutgers University
Newark, NJ
kaplansa@shp.rutgers.edu

David Killoran, PhD

Patient/Consumer Representative
for the ICF-Based Clinical Practice
Guidelines
Orthopaedic Section, APTA, Inc
La Crosse, WI
and
Professor Emeritus
Loyola Marymount University
Los Angeles, CA
david.killoran@lmu.edu

Leslie Torburn, DPT
Principal and Consultant
Silhouette Consulting, Inc
Sacramento, CA
torburn@yahoo.com

GUIDELINES EDITORS

Christine M. McDonough, PT, PhD
ICF-Based Clinical Practice Guidelines
Editor
Orthopaedic Section, APTA, Inc
La Crosse, WI
and
Assistant Professor of Physical Therapy
School of Health and Rehabilitation
Sciences
University of Pittsburgh
Pittsburgh, PA
cmm295@pitt.edu

Guy G. Simoneau, PT, PhD, ATC, FAPTA
ICF-Based Clinical Practice Guidelines
Editor
Orthopaedic Section, APTA, Inc
La Crosse, WI
and
Professor
Physical Therapy Department
Marquette University
Milwaukee, WI
guy.simoneau@marquette.edu

ACKNOWLEDGMENTS: *The authors would like to acknowledge the contributions of Dartmouth Biomedical Libraries Research and Education Librarians Heather Blunt and Pamela Bagley for their guidance and assistance in the design and implementation of the literature search. The authors would also like to acknowledge the assistance of Katherine Lynch, DPT, ATC, LAT, Assistant Athletic Trainer/Coordinator of Rehabilitation at Colorado College, for assistance in article reviewing for the search update.*

REFERENCES

- Abate M, Salini V, Schiavone C. Achilles tendinopathy in elderly subjects with type II diabetes: the role of sport activities. *Aging Clin Exp Res*. 2016;28:355-358. <https://doi.org/10.1007/s40520-015-0391-7>
- Abrahams Y, Laguet MJ, Prince S, Collins M. Polymorphisms within the COL5A1 3'-UTR that alters mRNA structure and the MIR608 gene are associated with Achilles tendinopathy. *Ann Hum Genet*. 2013;77:204-214. <https://doi.org/10.1111/ahg.12013>
- Albers IS, Zwerver J, Dierckx RL, Dekker JH, Van den Akker-Scheek I. Incidence and prevalence of lower extremity tendinopathy in a Dutch general practice population: a cross sectional study. *BMC Musculoskelet Disord*. 2016;17:16. <https://doi.org/10.1186/s12891-016-0885-2>
- Alfredson H, Cook J. A treatment algorithm for managing Achilles tendinopathy: new treatment options. *Br J Sports Med*. 2007;41:211-216. <https://doi.org/10.1136/bjsm.2007.035543>
- Ames PR, Longo UG, Denaro V, Maffulli N. Achilles tendon problems: not just an orthopaedic issue. *Disabil Rehabil*. 2008;30:1646-1650. <https://doi.org/10.1080/09638280701785882>
- Amin NH, McCullough KC, Mills GL, et al. The impact and functional outcomes of Achilles tendon pathology in National Basketball Association players. *Clin Res Foot Ankle*. 2016;4:205. <https://doi.org/10.4172/2329-910X.1000205>
- Andia I, Maffulli N. Clinical outcomes of biologic treatment for chronic tendinopathy. *Oper Tech Orthop*. 2016;26:98-109. <https://doi.org/10.1053/j.oto.2015.12.007>
- Arya S, Kulig K. Tendinopathy alters mechanical and material properties of the Achilles tendon. *J Appl Physiol* (1985). 2010;108:670-675. <https://doi.org/10.1152/jappphysiol.00259.2009>
- Aubry S, Nueffer JP, Tanter M, Becce F, Vidal C, Michel F. Viscoelasticity in Achilles tendonopathy: quantitative assessment by using real-time shear-wave elastography. *Radiology*. 2015;274:821-829. <https://doi.org/10.1148/radiol.14140434>
- Azevedo LB, Lambert MI, Vaughan CL, O'Connor CM, Schwellnus MP. Biomechanical variables associated with Achilles tendinopathy in runners. *Br J Sports Med*. 2009;43:288-292. <https://doi.org/10.1136/bjsm.2008.053421>
- Bagge J, Gaida JE, Danielson P, Alfredson H, Forsgren S. Physical activity level in Achilles tendinosis is associated with blood levels of pain-related factors: a pilot study. *Scand J Med Sci Sports*. 2011;21:e430-e438. <https://doi.org/10.1111/j.1600-0838.2011.01358.x>
- Bakkegaard M, Johannsen FE, Højgaard B, Langberg H. Ultrasonography as a prognostic and objective parameter in Achilles tendinopathy: a prospective observational study. *Eur J Radiol*. 2015;84:458-462. <https://doi.org/10.1016/j.ejrad.2014.11.028>
- Baur H, Müller S, Hirschl Müller A, Cassel M, Weber J, Mayer F. Comparison in lower leg neuromuscular activity between runners with unilateral mid-portion Achilles tendinopathy and healthy individuals. *J Electromyogr Kinesiol*. 2011;21:499-505. <https://doi.org/10.1016/j.jelekin.2010.11.010>
- Beyer R, Kongsgaard M, Hougs Kjaer B, Øhlenschläger T, Kjaer M, Magnusson SP. Heavy slow resistance versus eccentric training as treatment for Achilles tendinopathy: a randomized controlled trial. *Am J Sports Med*. 2015;43:1704-1711. <https://doi.org/10.1177/0363546515584760>
- Björklund E, Forsgren S, Alfredson H, Fowler CJ. Increased expression of cannabinoid CB1 receptors in Achilles tendinosis. *PLoS One*. 2011;6:e24731. <https://doi.org/10.1371/journal.pone.0024731>
- Boesen AP, Boesen MI, Torp-Pedersen S, et al. Associations between abnormal ultrasound color Doppler measures and tendon pain symptoms in badminton players during a season: a prospective cohort study. *Am J Sports Med*. 2012;40:548-555. <https://doi.org/10.1177/0363546511435478>
- Boesen AP, Hansen R, Boesen MI, Malliaras P, Langberg H. Effect of high-volume injection, platelet-rich plasma, and sham treatment in chronic midportion Achilles tendinopathy: a randomized double-blinded prospective study. *Am J Sports Med*. 2017;45:2034-2043. <https://doi.org/10.1177/0363546517702862>
- Brund RBK, Rasmussen S, Nielsen RO, Kersting UG, Laessoe U, Voigt M. Medial shoe-ground pressure and specific running injuries: a 1-year prospective cohort study. *J Sci Med Sport*. 2017;20:830-834. <https://doi.org/10.1016/j.jsams.2017.04.001>
- Buda R, Di Caprio F, Bedetti L, Mosca M, Giannini S. Foot overuse diseases in rock climbing: an epidemiologic study. *J Am Podiatr Med Assoc*. 2013;103:113-120. <https://doi.org/10.7547/1030113>
- Burssens A, Forsyth R, Bongaerts W, et al. Arguments for an increasing differentiation towards fibrocartilaginous components in midportion Achilles tendinopathy. *Knee Surg Sports Traumatol Arthrosc*. 2013;21:1459-1467. <https://doi.org/10.1007/s00167-012-2203-3>
- Calder JD, Stephen JM, van Dijk CN. Plantaris excision reduces pain in midportion Achilles tendinopathy even in the absence of plantaris tendinosis. *Orthop J Sports Med*. 2016;4:2325967116673978. <https://doi.org/10.1177/2325967116673978>
- Carcia CR, Martin RL, Houck J, Wukich DK. Achilles pain, stiffness, and muscle power deficits: Achilles tendinitis. *J Orthop Sports Phys Ther*. 2010;40:A1-A26. <https://doi.org/10.2519/jospt.2010.0305>
- Cassel M, Baur H, Hirschl Müller A, Carlsohn A, Fröhlich K, Mayer F. Prevalence of Achilles and patellar tendinopathy and their association to intratendinous changes in adolescent athletes. *Scand J Med Sci Sports*. 2015;25:e310-e318. <https://doi.org/10.1111/sms.12318>
- Chan O, Morton S, Pritchard M, et al. Intratendinous tears of the Achilles tendon - a new pathology? Analysis of a large 4-year cohort. *Muscles Ligaments Tendons J*. 2017;7:53-61. <https://doi.org/10.11138/mltj/2017.71.053>
- Chang YI, Kulig K. The neuromechanical adaptations to Achilles tendinosis. *J Physiol*. 2015;593:3373-3387. <https://doi.org/10.1113/JP270220>
- Chaudhry FA. Effectiveness of dry needling and high-volume image-guided injection in the management of chronic mid-portion Achilles tendinopathy in adult population: a literature review. *Eur J Orthop Surg Traumatol*. 2017;27:441-448. <https://doi.org/10.1007/s00590-017-1957-1>
- Cheatham SW, Lee M, Cain M, Baker R. The efficacy of instrument assisted soft tissue mobilization: a systematic review. *J Can Chiropr Assoc*. 2016;60:200-211.
- Child S, Bryant AL, Clark RA, Crossley KM. Mechanical properties of the Achilles tendon aponeurosis are altered in athletes with Achilles tendinopathy. *Am J Sports Med*. 2010;38:1885-1893. <https://doi.org/10.1177/0363546510366234>
- Christensen J, Alfredson H, Andersson G. Protease-activated receptors in the Achilles tendon—a potential explanation for the excessive pain signalling in tendinopathy. *Mol Pain*. 2015;11:13. <https://doi.org/10.1186/s12990-015-0007-4>
- Clement DB, Taunton JE, Smart GW. Achilles tendinitis and peritendinitis: etiology and treatment. *Am J Sports Med*. 1984;12:179-184. <https://doi.org/10.1177/036354658401200301>
- Comin J, Cook JL, Malliaras P, et al. The prevalence and clinical significance of sonographic tendon abnormalities in asymptomatic ballet dancers: a 24-month longitudinal study. *Br J Sports Med*. 2013;47:89-92. <https://doi.org/10.1136/bjsports-2012-091303>
- Coombes BK, Bisset L, Vicenzino B. Efficacy and safety of corticosteroid injections and other injections for management of tendinopathy: a systematic review of randomised controlled trials. *Lancet*. 2010;376:1751-

1767. [https://doi.org/10.1016/S0140-6736\(10\)61160-9](https://doi.org/10.1016/S0140-6736(10)61160-9)
33. Coombes BK, Tucker K, Vicenzino B, et al. Achilles and patellar tendinopathy display opposite changes in elastic properties: a shear wave elastography study. *Scand J Med Sci Sports*. 2018;28:1201-1208. <https://doi.org/10.1111/sms.12986>
34. Creaby MW, Honeywill C, Franettovich Smith MM, Schache AG, Crossley KM. Hip biomechanics are altered in male runners with Achilles tendinopathy. *Med Sci Sports Exerc*. 2017;49:549-554. <https://doi.org/10.1249/MSS.0000000000001126>
35. Dakin SG, Newton J, Martinez FO, et al. Chronic inflammation is a feature of Achilles tendinopathy and rupture. *Br J Sports Med*. 2018;52:359-367. <https://doi.org/10.1136/bjsports-2017-098161>
36. Dalbeth N, Kalluru R, Aati O, Horne A, Doyle AJ, McQueen FM. Tendon involvement in the feet of patients with gout: a dual-energy CT study. *Ann Rheum Dis*. 2013;72:1545-1548. <https://doi.org/10.1136/annrheumdis-2012-202786>
37. Dean BJ, Franklin SL, Carr AJ. The peripheral neuronal phenotype is important in the pathogenesis of painful human tendinopathy: a systematic review. *Clin Orthop Relat Res*. 2013;471:3036-3046. <https://doi.org/10.1007/s11999-013-3010-y>
38. Debenham J, Butler P, Mallows A, Wand BM. Disrupted tactile acuity in people with Achilles tendinopathy: a preliminary case-control investigation. *J Orthop Sports Phys Ther*. 2016;46:1061-1064. <https://doi.org/10.2519/jospt.2016.6514>
39. Debenham JR, Travers MJ, Gibson W, Campbell A, Allison GT. Achilles tendinopathy alters stretch shortening cycle behaviour during a sub-maximal hopping task. *J Sci Med Sport*. 2016;19:69-73. <https://doi.org/10.1016/j.jsams.2014.11.391>
40. de Jonge S, de Vos RJ, Van Schie HT, Verhaar JA, Weir A, Tol JL. One-year follow-up of a randomised controlled trial on added splinting to eccentric exercises in chronic midportion Achilles tendinopathy. *Br J Sports Med*. 2010;44:673-677. <https://doi.org/10.1136/bjsm.2008.052142>
41. de Jonge S, de Vos RJ, Weir A, et al. One-year follow-up of platelet-rich plasma treatment in chronic Achilles tendinopathy: a double-blind randomized placebo-controlled trial. *Am J Sports Med*. 2011;39:1623-1629. <https://doi.org/10.1177/0363546511404877>
42. de Jonge S, Tol JL, Weir A, Waarsing JH, Verhaar JA, de Vos RJ. The tendon structure returns to asymptomatic values in nonoperatively treated Achilles tendinopathy but is not associated with symptoms: a prospective study. *Am J Sports Med*. 2015;43:2950-2958. <https://doi.org/10.1177/0363546515605077>
43. de Jonge S, van den Berg C, de Vos RJ, et al. Incidence of midportion Achilles tendinopathy in the general population. *Br J Sports Med*. 2011;45:1026-1028. <https://doi.org/10.1136/bjsports-2011-090342>
44. De Jonge S, Warnars JL, De Vos RJ, et al. Relationship between neovascularization and clinical severity in Achilles tendinopathy in 556 paired measurements. *Scand J Med Sci Sports*. 2014;24:773-778. <https://doi.org/10.1111/sms.12072>
45. De Marchi A, Pozza S, Cenna E, et al. In Achilles tendinopathy, the neovascularization, detected by contrast-enhanced ultrasound (CEUS), is abundant but not related to symptoms. *Knee Surg Sports Traumatol Arthrosc*. In press. <https://doi.org/10.1007/s00167-017-4710-8>
46. de Mos M, Joosten LA, Oppers-Walgreen B, et al. Tendon degeneration is not mediated by regulation of Toll-like receptors 2 and 4 in human tenocytes. *J Orthop Res*. 2009;27:1043-1047. <https://doi.org/10.1002/jor.20834>
47. de Mos M, Koevoet W, van Schie HT, et al. In vitro model to study chondrogenic differentiation in tendinopathy. *Am J Sports Med*. 2009;37:1214-1222. <https://doi.org/10.1177/0363546508331137>
48. de Vos RJ, Heijboer MP, Weinans H, Verhaar JA, van Schie JT. Tendon structure's lack of relation to clinical outcome after eccentric exercises in chronic midportion Achilles tendinopathy. *J Sport Rehabil*. 2012;21:34-43. <https://doi.org/10.1123/jsr.21.1.34>
49. de Vos RJ, Weir A, Tol JL, Verhaar JA, Weinans H, van Schie HT. No effects of PRP on ultrasonographic tendon structure and neovascularisation in chronic midportion Achilles tendinopathy. *Br J Sports Med*. 2011;45:387-392. <https://doi.org/10.1136/bjsm.2010.076398>
50. de Vos RJ, Weir A, van Schie HT, et al. Platelet-rich plasma injection for chronic Achilles tendinopathy: a randomized controlled trial. *JAMA*. 2010;303:144-149. <https://doi.org/10.1001/jama.2009.1986>
51. De Zordo T, Chhem R, Smekal V, et al. Real-time sonoelastography: findings in patients with symptomatic Achilles tendons and comparison to healthy volunteers. *Ultraschall Med*. 2010;31:394-400. <https://doi.org/10.1055/s-0028-1109809>
52. Di Matteo B, Filardo G, Kon E, Marcacci M. Platelet-rich plasma: evidence for the treatment of patellar and Achilles tendinopathy—a systematic review. *Musculoskelet Surg*. 2015;99:1-9. <https://doi.org/10.1007/s12306-014-0340-1>
53. Dirrichs T, Quack V, Gatz M, Tingart M, Kuhl CK, Schradings S. Shear wave elastography (SWE) for the evaluation of patients with tendinopathies. *Acad Radiol*. 2016;23:1204-1213. <https://doi.org/10.1016/j.acra.2016.05.012>
54. Divani K, Chan O, Padhiar N, et al. Site of maximum neovascularisation correlates with the site of pain in recalcitrant mid-tendon Achilles tendinopathy. *Man Ther*. 2010;15:463-468. <https://doi.org/10.1016/j.math.2010.03.011>
55. Docking SI, Cook J. Pathological tendons maintain sufficient aligned fibrillar structure on ultrasound tissue characterization (UTC). *Scand J Med Sci Sports*. 2016;26:675-683. <https://doi.org/10.1111/sms.12491>
56. Docking SI, Rosengarten SD, Daffy J, Cook J. Structural integrity is decreased in both Achilles tendons in people with unilateral Achilles tendinopathy. *J Sci Med Sport*. 2015;18:383-387. <https://doi.org/10.1016/j.jsams.2014.06.004>
57. Dogramaci Y, Kalaci A, Küçükbaş N, İnandı T, Eşen E, Yanat AN. Validation of the VISA-A questionnaire for Turkish language: the VISA-A-Tr study. *Br J Sports Med*. 2011;45:453-455. <https://doi.org/10.1136/bjsm.2009.060236>
58. Dowling GJ, Murley GS, Munteanu SE, et al. Dynamic foot function as a risk factor for lower limb overuse injury: a systematic review. *J Foot Ankle Res*. 2014;7:53. <https://doi.org/10.1186/s13047-014-0053-6>
59. Ebbesen BH, Mølgaard CM, Olesen JL, Gregersen HE, Simonsen O. No beneficial effect of Polidocanol treatment in Achilles tendinopathy: a randomised controlled trial. *Knee Surg Sports Traumatol Arthrosc*. In press. <https://doi.org/10.1007/s00167-017-4675-7>
60. Eickler R, Pomeranz SJ. Achilles tendinitis. *J Surg Orthop Adv*. 2015;24:198-202.
61. El Khoury L, Posthumus M, Collins M, Handley CJ, Cook J, Raleigh SM. Polymorphic variation within the ADAMTS2, ADAMTS14, ADAMTS5, ADAM12 and TIMP2 genes and the risk of Achilles tendon pathology: a genetic association study. *J Sci Med Sport*. 2013;16:493-498. <https://doi.org/10.1016/j.jsams.2013.02.006>
62. El Khoury L, Ribbans WJ, Raleigh SM. MMP3 and TIMP2 gene variants as predisposing factors for Achilles tendon pathologies: attempted replication study in a British case-control cohort. *Meta Gene*. 2016;9:52-55. <https://doi.org/10.1016/j.mgene.2016.03.007>
63. Emerson C, Morrissey D, Perry M, Jalan R. Ultrasonographically detected changes in Achilles tendons and self reported symptoms in elite gymnasts compared with controls – an observational study. *Man Ther*. 2010;15:37-

42. <https://doi.org/10.1016/j.math.2009.05.008>
64. Fahlström M, Lorentzon R, Alfredson H. Painful conditions in the Achilles tendon region in elite badminton players. *Am J Sports Med*. 2002;30:51-54. <https://doi.org/10.1177/03635465020300012201>
65. Filardo G, Di Matteo B, Kon E, Merli G, Marcacci M. Platelet-rich plasma in tendon-related disorders: results and indications. *Knee Surg Sports Traumatol Arthrosc*. In press. <https://doi.org/10.1007/s00167-016-4261-4>
66. Firth BL, Dingley P, Davies ER, Lewis JS, Alexander CM. The effect of kinesiotope on function, pain, and motoneuronal excitability in healthy people and people with Achilles tendinopathy. *Clin J Sport Med*. 2010;20:416-421. <https://doi.org/10.1097/JSM.0b013e3181f479b0>
67. Fischer MA, Pfirrmann CW, Espinosa N, Raptis DA, Buck FM. Dixon-based MRI for assessment of muscle-fat content in phantoms, healthy volunteers and patients with achillodynia: comparison to visual assessment of calf muscle quality. *Eur Radiol*. 2014;24:1366-1375. <https://doi.org/10.1007/s00330-014-3121-1>
68. Fordham S, Garbutt G, Lopes P. Epidemiology of injuries in adventure racing athletes. *Br J Sports Med*. 2004;38:300-303. <https://doi.org/10.1136/bjsm.2002.003350>
69. Franceschi F, Papalia R, Paciotti M, et al. Obesity as a risk factor for tendinopathy: a systematic review. *Int J Endocrinol*. 2014;2014:670262. <https://doi.org/10.1155/2014/670262>
70. Frantovich Smith MM, Honeywill C, Wyndow N, Crossley KM, Creaby MW. Neuromotor control of gluteal muscles in runners with Achilles tendinopathy. *Med Sci Sports Exerc*. 2014;46:594-599. <https://doi.org/10.1249/MSS.0000000000000133>
71. Frizziero A, Trainito S, Oliva F, Nicoli Aldini N, Masiero S, Maffulli N. The role of eccentric exercise in sport injuries rehabilitation. *Br Med Bull*. 2014;110:47-75. <https://doi.org/10.1093/bmb/ldu006>
72. Gaida JE, Alfredson H, Forsgren S, Cook JL. A pilot study on biomarkers for tendinopathy: lower levels of serum TNF- α and other cytokines in females but not males with Achilles tendinopathy. *BMC Sports Sci Med Rehabil*. 2016;8:5. <https://doi.org/10.1186/s13102-016-0026-0>
73. Gaida JE, Alfredson L, Kiss ZS, Wilson AM, Alfredson H, Cook JL. Dyslipidemia in Achilles tendinopathy is characteristic of insulin resistance. *Med Sci Sports Exerc*. 2009;41:1194-1197. <https://doi.org/10.1249/MSS.0b013e31819794c3>
74. Gaida JE, Ashe MC, Bass SL, Cook JL. Is adiposity an under-recognized risk factor for tendinopathy? A systematic review. *Arthritis Rheum*. 2009;61:840-849. <https://doi.org/10.1002/art.24518>
75. Gaida JE, Bagge J, Purdam C, Cook J, Alfredson H, Forsgren S. Evidence of the TNF- α system in the human Achilles tendon: expression of TNF- α and TNF receptor at both protein and mRNA levels in the tenocytes. *Cells Tissues Organs*. 2012;196:339-352. <https://doi.org/10.1159/000335475>
76. Gajhede-Knudsen M, Ekstrand J, Magnusson H, Maffulli N. Recurrence of Achilles tendon injuries in elite male football players is more common after early return to play: an 11-year follow-up of the UEFA Champions League injury study. *Br J Sports Med*. 2013;47:763-768. <https://doi.org/10.1136/bjsports-2013-092271>
77. Galletti S, Oliva F, Masiero S, et al. Sonoelastography in the diagnosis of tendinopathies: an added value. *Muscles Ligaments Tendons J*. 2015;5:325-330. <https://doi.org/10.11138/mltj/2015.5.4.325>
78. Gärdin A, Brismar TB, Movin T, Shalabi A. Dynamic contrast enhanced magnetic resonance imaging in chronic Achilles tendinosis. *BMC Med Imaging*. 2013;13:39. <https://doi.org/10.1186/1471-2342-13-39>
79. Gärdin A, Movin T, Svensson L, Shalabi A. The long-term clinical and MRI results following eccentric calf muscle training in chronic Achilles tendinosis. *Skeletal Radiol*. 2010;39:435-442. <https://doi.org/10.1007/s00256-009-0798-3>
80. Gärdin A, Rasinski P, Berglund J, Shalabi A, Schulte H, Brismar TB. T₂* relaxation time in Achilles tendinosis and controls and its correlation with clinical score. *J Magn Reson Imaging*. 2016;43:1417-1422. <https://doi.org/10.1002/jmri.25104>
81. Gerdesmeyer L, Mittermayr R, Fuerst M, et al. Current evidence of extracorporeal shock wave therapy in chronic Achilles tendinopathy. *Int J Surg*. 2015;24:154-159. <https://doi.org/10.1016/j.jsu.2015.07.718>
82. Gouveia-Figueira S, Nording ML, Gaida JE, Forsgren S, Alfredson H, Fowler CJ. Serum levels of oxylipins in Achilles tendinopathy: an exploratory study. *PLoS One*. 2015;10:e0123114. <https://doi.org/10.1371/journal.pone.0123114>
83. Grigg NL, Wearing SC, O'Toole JM, Smeathers JE. Achilles tendinopathy modulates force frequency characteristics of eccentric exercise. *Med Sci Sports Exerc*. 2013;45:520-526. <https://doi.org/10.1249/MSS.0b013e31827795a7>
84. Grigg NL, Wearing SC, Smeathers JE. Achilles tendinopathy has an aberrant strain response to eccentric exercise. *Med Sci Sports Exerc*. 2012;44:12-17. <https://doi.org/10.1249/MSS.0b013e318227fa8c>
85. Grosse U, Syha R, Martirosian P, et al. Ultrashort echo time MR imaging with off-resonance saturation for characterization of pathologically altered Achilles tendons at 3 T. *Magn Reson Med*. 2013;70:184-192. <https://doi.org/10.1002/mrm.24435>
86. Habets B, Smits HW, Backx FJG, van Cingel REH, Huisstede BMA. Hip muscle strength is decreased in middle-aged recreational male athletes with midportion Achilles tendinopathy: a cross-sectional study. *Phys Ther Sport*. 2017;25:55-61. <https://doi.org/10.1016/j.ptsp.2016.09.008>
87. Habets B, van Cingel RE. Eccentric exercise training in chronic mid-portion Achilles tendinopathy: a systematic review on different protocols. *Scand J Med Sci Sports*. 2015;25:3-15. <https://doi.org/10.1111/sms.12208>
88. Hay M, Patricios J, Collins R, et al. Association of type XI collagen genes with chronic Achilles tendinopathy in independent populations from South Africa and Australia. *Br J Sports Med*. 2013;47:569-574. <https://doi.org/10.1136/bjsports-2013-092379>
89. Heales LJ, Lim EC, Hodges PW, Vicenzino B. Sensory and motor deficits exist on the non-injured side of patients with unilateral tendon pain and disability—implications for central nervous system involvement: a systematic review with meta-analysis. *Br J Sports Med*. 2014;48:1400-1406. <https://doi.org/10.1136/bjsports-2013-092535>
90. Helfenstein-Didier C, Andrade RJ, Brum J, et al. In vivo quantification of the shear modulus of the human Achilles tendon during passive loading using shear wave dispersion analysis. *Phys Med Biol*. 2016;61:2485-2496. <https://doi.org/10.1088/0031-9155/61/6/2485>
91. Hoffmann A, Mamisch N, Buck FM, Espinosa N, Pfirrmann CW, Zanetti M. Oedema and fatty degeneration of the soleus and gastrocnemius muscles on MR images in patients with Achilles tendon abnormalities. *Eur Radiol*. 2011;21:1996-2003. <https://doi.org/10.1007/s00330-011-2136-0>
92. Holmes GB, Lin J. Etiologic factors associated with symptomatic Achilles tendinopathy. *Foot Ankle Int*. 2006;27:952-959. <https://doi.org/10.1177/107110070602701115>
93. House C, Reece A, Roiz de Sa D. Shock-absorbing insoles reduce the incidence of lower limb overuse injuries sustained during Royal Marine training. *Mil Med*. 2013;178:683-689. <https://doi.org/10.7205/MILMED-D-12-00361>
94. Hutchison AM, Evans R, Bodger O, et al. What is the best clinical test for Achilles tendinopathy? *Foot Ankle Surg*. 2013;19:112-117. <https://doi.org/10.1016/j.fas.2012.12.006>
95. Hutchison AM, Pallister I, Evans RM, et al. Intense pulsed light treatment

of chronic mid-body Achilles tendinopathy: a double blind randomised placebo-controlled trial. *Bone Joint J.* 2013;95-B:504-509. <https://doi.org/10.1302/0301-620X.95B4.30558>

96. Intziogianni K, Cassel M, Rauf S, et al. Influence of age and pathology on Achilles tendon properties during a single-leg jump. *Int J Sports Med.* 2016;37:973-978. <https://doi.org/10.1055/s-0042-108198>
97. Iversen JV, Bartels EM, Jørgensen JE, et al. Danish VISA-A questionnaire with validation and reliability testing for Danish-speaking Achilles tendinopathy patients. *Scand J Med Sci Sports.* 2016;26:1423-1427. <https://doi.org/10.1111/sms.12576>
98. Jewson JL, Lambert EA, Docking S, Storr M, Lambert GW, Gaida JE. Pain duration is associated with increased muscle sympathetic nerve activity in patients with Achilles tendinopathy. *Scand J Med Sci Sports.* 2017;27:1942-1949. <https://doi.org/10.1111/sms.12820>
99. Jewson JL, Lambert GW, Storr M, Gaida JE. The sympathetic nervous system and tendinopathy: a systematic review. *Sports Med.* 2015;45:727-743. <https://doi.org/10.1007/s40279-014-0300-9>
100. Jhingan S, Perry M, O'Driscoll G, et al. Thicker Achilles tendons are a risk factor to develop Achilles tendinopathy in elite professional soccer players. *Muscles Ligaments Tendons J.* 2011;1:51-56.
101. Johansson C. Injuries in elite orienteers. *Am J Sports Med.* 1986;14:410-415. <https://doi.org/10.1177/036354658601400515>
102. Kachlik D, Baca V, Cepelik M, et al. Clinical anatomy of the retrocalcaneal bursa. *Surg Radiol Anat.* 2008;30:347-353. <https://doi.org/10.1007/s00276-008-0335-4>
103. Kaux JF, Delvaux F, Oppong-Kyei J, et al. Validity and reliability of the French translation of the VISA-A questionnaire for Achilles tendinopathy. *Disabil Rehabil.* 2016;38:2593-2599. <https://doi.org/10.3109/09638288.2016.1138553>
104. Kayser R, Mahlfeld K, Heyde CE. Partial rupture of the proximal Achilles tendon: a differential diagnostic problem in ultrasound imaging. *Br J Sports Med.* 2005;39:838-842. <https://doi.org/10.1136/bjsm.2005.018416>
105. Kim S, Yu J. Changes of gait parameters and lower limb dynamics in recreational runners with Achilles tendinopathy. *J Sports Sci Med.* 2015;14:284-289.
106. Klein EE, Weil L, Jr., Weil LS, Sr., Fleischer AE. Body mass index and Achilles tendonitis: a 10-year retrospective analysis. *Foot Ankle Spec.* 2013;6:276-282. <https://doi.org/10.1177/1938640013489343>
107. Knobloch K, Schreibmueller L, Kraemer R, Jagodzinski M, Vogt PM, Redeker J. Gender and eccentric training in Achilles mid-portion tendinopathy. *Knee Surg Sports Traumatol Arthrosc.* 2010;18:648-655. <https://doi.org/10.1007/s00167-009-1006-7>
108. Kozlovskaja M, Vlahovich N, Ashton KJ, Hughes DC. Biomedical risk factors of Achilles tendinopathy in physically active people: a systematic review. *Sports Med Open.* 2017;3:20. <https://doi.org/10.1186/s40798-017-0087-y>
109. Kraemer R, Knobloch K. A soccer-specific balance training program for hamstring muscle and patellar and Achilles tendon injuries: an intervention study in premier league female soccer. *Am J Sports Med.* 2009;37:1384-1393. <https://doi.org/10.1177/0363546509333012>
110. Kraemer R, Wuerfel W, Lorenzen J, Busche M, Vogt PM, Knobloch K. Analysis of hereditary and medical risk factors in Achilles tendinopathy and Achilles tendon ruptures: a matched pair analysis. *Arch Orthop Trauma Surg.* 2012;132:847-853. <https://doi.org/10.1007/s00402-012-1476-9>
111. Kraggsnaes MS, Fredberg U, Stribolt K, Kjaer SG, Bendix K, Ellingsen T. Stereological quantification of immune-competent cells in baseline biopsy specimens from Achilles tendons: results from patients with chronic tendinopathy followed for more than 4 years. *Am J Sports Med.* 2014;42:2435-2445. <https://doi.org/10.1177/0363546514542329>
112. Krogh TP, Ellingsen T, Christensen R, Jensen P, Fredberg U. Ultrasound-guided injection therapy of Achilles tendinopathy with platelet-rich plasma or saline: a randomized, blinded, placebo-controlled trial. *Am J Sports Med.* 2016;44:1990-1997. <https://doi.org/10.1177/0363546516647958>
113. Krolo I, Visković K, Ikić D, Klarić-Custović R, Marotti M, Cicvara T. The risk of sports activities--the injuries of the Achilles tendon in sportsmen. *Col Antropol.* 2007;31:275-278.
114. Kujala UM, Sarna S, Kaprio J. Cumulative incidence of Achilles tendon rupture and tendinopathy in male former elite athletes. *Clin J Sport Med.* 2005;15:133-135.
115. Kulig K, Loudon JK, Popovich JM, Jr., Pollard CD, Winder BR. Dancers with Achilles tendinopathy demonstrate altered lower extremity takeoff kinematics. *J Orthop Sports Phys Ther.* 2011;41:606-613. <https://doi.org/10.2519/jospt.2011.3580>
116. Kvist M. Achilles tendon injuries in athletes. *Ann Chir Gynaecol.* 1991;80:188-201.
117. Lang TR, Cook J, Rio E, Gaida JE. What tendon pathology is seen on imaging in people who have taken fluoroquinolones? A systematic review. *Fundam Clin Pharmacol.* 2017;31:4-16. <https://doi.org/10.1111/fcp.12228>
118. Leach RE, James S, Wasilewski S. Achilles tendinitis. *Am J Sports Med.* 1981;9:93-98. <https://doi.org/10.1177/036354658100900204>
119. Legerlotz K, Jones ER, Screen HR, Riley GP. Increased expression of IL-6 family members in tendon pathology. *Rheumatology (Oxford).* 2012;51:1161-1165. <https://doi.org/10.1093/rheumatology/kes002>
120. Lewis T, Cook J. Fluoroquinolones and tendinopathy: a guide for athletes and sports clinicians and a systematic review of the literature. *J Athl Train.* 2014;49:422-427. <https://doi.org/10.4085/1062-6050-49.2.09>
121. Longo UG, Rittweger J, Garau G, et al. No influence of age, gender, weight, height, and impact profile in Achilles tendinopathy in masters track and field athletes. *Am J Sports Med.* 2009;37:1400-1405. <https://doi.org/10.1177/0363546509332250>
122. Lopes AD, Hespanhol Junior LC, Yeung SS, Costa LO. What are the main running-related musculoskeletal injuries? A systematic review. *Sports Med.* 2012;42:891-905. <https://doi.org/10.2165/11631170-000000000-00000>
123. Lorimer AV, Hume PA. Stiffness as a risk factor for Achilles tendon injury in running athletes. *Sports Med.* 2016;46:1921-1938. <https://doi.org/10.1007/s40279-016-0526-9>
124. Lowes DA, Wallace C, Murphy MP, Webster NR, Galley HF. The mitochondria targeted antioxidant MitoQ protects against fluoroquinolone-induced oxidative stress and mitochondrial membrane damage in human Achilles tendon cells. *Free Radic Res.* 2009;43:323-328. <https://doi.org/10.1080/10715760902736275>
125. Luck MD, Gordon AG, Blebea JS, Dalinka MK. High association between accessory soleus muscle and Achilles tendinopathy. *Skeletal Radiol.* 2008;37:1129-1133. <https://doi.org/10.1007/s00256-008-0554-0>
126. MacDermid JC, Silbernagel KG. Outcome evaluation in tendinopathy: foundations of assessment and a summary of selected measures. *J Orthop Sports Phys Ther.* 2015;45:950-964. <https://doi.org/10.2519/jospt.2015.6054>
127. Maffulli N, Kenward MG, Testa V, Capasso G, Regine R, King JB. Clinical diagnosis of Achilles tendinopathy with tendinosis. *Clin J Sport Med.* 2003;13:11-15.
128. Maffulli N, Wong J, Almekinders LC. Types and epidemiology of tendinopathy. *Clin Sports Med.* 2003;22:675-692. [https://doi.org/10.1016/S0278-5919\(03\)00004-8](https://doi.org/10.1016/S0278-5919(03)00004-8)

129. Magnan B, Bondi M, Pierantoni S, Samaila E. The pathogenesis of Achilles tendinopathy: a systematic review. *Foot Ankle Surg.* 2014;20:154-159. <https://doi.org/10.1016/j.fas.2014.02.010>
130. Magnussen RA, Dunn WR, Thomson AB. Nonoperative treatment of midportion Achilles tendinopathy: a systematic review. *Clin J Sport Med.* 2009;19:54-64. <https://doi.org/10.1097/JSM.0b013e31818ef090>
131. Malliaras P, Barton CJ, Reeves ND, Langberg H. Achilles and patellar tendinopathy loading programmes: a systematic review comparing clinical outcomes and identifying potential mechanisms for effectiveness. *Sports Med.* 2013;43:267-286. <https://doi.org/10.1007/s40279-013-0019-z>
132. Martin R. Considerations for differential diagnosis of an ankle sprain in the adolescent. *Orthop Phys Ther Pract.* 2004;16:21-22.
133. Masci L, Spang C, van Schie HT, Alfredson H. How to diagnose plantaris tendon involvement in midportion Achilles tendinopathy - clinical and imaging findings. *BMC Musculoskelet Disord.* 2016;17:97. <https://doi.org/10.1186/s12891-016-0955-5>
134. McAuliffe S, McCreesh K, Culloy F, Purtill H, O'Sullivan K. Can ultrasound imaging predict the development of Achilles and patellar tendinopathy? A systematic review and meta-analysis. *Br J Sports Med.* 2016;50:1516-1523. <https://doi.org/10.1136/bjsports-2016-096288>
135. McClure PW, Michener LA. Staged approach for rehabilitation classification: shoulder disorders (STAR-Shoulder). *Phys Ther.* 2015;95:791-800. <https://doi.org/10.2522/ptj.20140156>
136. Mehta SP, Fulton A, Quach C, Thistle M, Toledo C, Evans NA. Measurement properties of the Lower Extremity Functional Scale: a systematic review. *J Orthop Sports Phys Ther.* 2016;46:200-216. <https://doi.org/10.2519/jospt.2016.6165>
137. Morton S, Chan O, Webborn N, Pritchard M, Morrissey D. Tears of the fascia cruris demonstrate characteristic sonographic features: a case series analysis. *Muscles Ligaments Tendons J.* 2015;5:299-304. <https://doi.org/10.11138/mltj/2015.5.4.299>
138. Mucha MD, Caldwell W, Schlueter EL, Walters C, Hassen A. Hip abductor strength and lower extremity running related injury in distance runners: a systematic review. *J Sci Med Sport.* 2017;20:349-355. <https://doi.org/10.1016/j.jsams.2016.09.002>
139. Munteanu SE, Scott LA, Bonanno DR, et al. Effectiveness of customised foot orthoses for Achilles tendinopathy: a randomised controlled trial. *Br J Sports Med.* 2015;49:989-994. <https://doi.org/10.1136/bjsports-2014-093845>
140. Nielsen RO, Rønnow L, Rasmussen S, Lind M. A prospective study on time to recovery in 254 injured novice runners. *PLoS One.* 2014;9:e99877. <https://doi.org/10.1371/journal.pone.0099877>
141. Nuri L, Obst SJ, Newsham-West R, Barrett RS. The tendinopathic Achilles tendon does not remain iso-volumetric upon repeated loading: insights from 3D ultrasound. *J Exp Biol.* 2017;220:3053-3061. <https://doi.org/10.1242/jeb.159764>
142. Olewnik L, Wysiadecki G, Polguy M, Topol M. Anatomic study suggests that the morphology of the plantaris tendon may be related to Achilles tendonitis. *Surg Radiol Anat.* 2017;39:69-75. <https://doi.org/10.1007/s00276-016-1682-1>
143. Ooi CC, Schneider ME, Malliaras P, Chadwick M, Connell DA. Diagnostic performance of axial-strain sonoelastography in confirming clinically diagnosed Achilles tendinopathy: comparison with B-mode ultrasound and color Doppler imaging. *Ultrasound Med Biol.* 2015;41:15-25. <https://doi.org/10.1016/j.ultrasmedbio.2014.08.019>
144. Owens RF, Jr., Ginnetti J, Conti SF, Latona C. Clinical and magnetic resonance imaging outcomes following platelet rich plasma injection for chronic midsubstance Achilles tendinopathy. *Foot Ankle Int.* 2011;32:1032-1039. <https://doi.org/10.3113/FAI.2011.1032>
145. Paavola M, Kannus P, Paakkala T, Pasanen M, Järvinen M. Long-term prognosis of patients with Achilles tendinopathy. *Am J Sports Med.* 2000;28:634-642. <https://doi.org/10.1177/03635465000280050301>
146. Pearce CJ, Ismail M, Calder JD. Is apoptosis the cause of noninsertional Achilles tendinopathy? *Am J Sports Med.* 2009;37:2440-2444. <https://doi.org/10.1177/0363546509340264>
147. Pearson J, Rowlands D, Highet R. Autologous blood injection to treat Achilles tendinopathy? A randomized controlled trial. *J Sport Rehabil.* 2012;21:218-224. <https://doi.org/10.1123/jsr.21.3.218>
148. Petersen W, Welp R, Rosenbaum D. Chronic Achilles tendinopathy: a prospective randomized study comparing the therapeutic effect of eccentric training, the AirHeel brace, and a combination of both. *Am J Sports Med.* 2007;35:1659-1667. <https://doi.org/10.1177/0363546507303558>
149. Phillips B, Ball C, Sackett D, et al. Oxford Centre for Evidence-based Medicine - Levels of Evidence (March 2009). Available at: <http://www.cebm.net/index.aspx?o=1025>. Accessed August 4, 2009.
150. Pingel J, Fredberg U, Qvortrup K, et al. Local biochemical and morphological differences in human Achilles tendinopathy: a case control study. *BMC Musculoskelet Disord.* 2012;13:53. <https://doi.org/10.1186/1471-2474-13-53>
151. Pingel J, Harrison A, Simonsen L, Suetta C, Bülow J, Langberg H. The microvascular volume of the Achilles tendon is increased in patients with tendinopathy at rest and after a 1-hour treadmill run. *Am J Sports Med.* 2013;41:2400-2408. <https://doi.org/10.1177/0363546513498988>
152. Pingel J, Petersen MC, Fredberg U, et al. Inflammatory and metabolic alterations of Kager's fat pad in chronic Achilles tendinopathy. *PLoS One.* 2015;10:e0127811. <https://doi.org/10.1371/journal.pone.0127811>
153. Plinsinga ML, van Wilgen CP, Brink MS, et al. Patellar and Achilles tendinopathies are predominantly peripheral pain states: a blinded case control study of somatosensory and psychological profiles. *Br J Sports Med.* 2018;52:284-291. <https://doi.org/10.1136/bjsports-2016-097163>
154. Pollock N, Dijkstra P, Calder J, Chakraverty R. Plantaris injuries in elite UK track and field athletes over a 4-year period: a retrospective cohort study. *Knee Surg Sports Traumatol Arthrosc.* 2016;24:2287-2292. <https://doi.org/10.1007/s00167-014-3409-3>
155. Posthumus M, Collins M, Cook J, et al. Components of the transforming growth factor- β family and the pathogenesis of human Achilles tendon pathology—a genetic association study. *Rheumatology (Oxford).* 2010;49:2090-2097. <https://doi.org/10.1093/rheumatology/keq072>
156. Posthumus M, September AV, Schwellnus MP, Collins M. Investigation of the Sp1-binding site polymorphism within the COL1A1 gene in participants with Achilles tendon injuries and controls. *J Sci Med Sport.* 2009;12:184-189. <https://doi.org/10.1016/j.jsams.2007.12.006>
157. Rahim M, El Khoury LY, Raleigh SM, et al. Human genetic variation, sport and exercise medicine, and Achilles tendinopathy: role for angiogenesis-associated genes. *OMICS.* 2016;20:520-527. <https://doi.org/10.1089/omi.2016.0116>
158. Ram R, Meeuwisse W, Patel C, Wiseman DA, Wiley JP. The limited effectiveness of a home-based eccentric training for treatment of Achilles tendinopathy. *Clin Invest Med.* 2013;36:E197-E206.
159. Redler LH, Thompson SA, Hsu SH, Ahmad CS, Levine WN. Platelet-rich plasma therapy: a systematic literature review and evidence for clinical use. *Phys Sportsmed.* 2011;39:42-51. <https://doi.org/10.3810/psm.2011.02.1861>
160. Reiman M, Burgi C, Strube E, et al. The utility of clinical measures for the diagnosis of Achilles tendon injuries: a systematic review with meta-analysis. *J Athl Train.* 2014;49:820-829. <https://doi.org/10.4085/1062-6050-49.3.36>

161. Richards PJ, Braid JC, Carmont MR, Maffulli N. Achilles tendon ossification: pathology, imaging and aetiology. *Disabil Rehabil*. 2008;30:1651-1665. <https://doi.org/10.1080/09638280701785866>
162. Richards PJ, McCall IW, Day C, Belcher J, Maffulli N. Longitudinal micro-vascularity in Achilles tendinopathy (power Doppler ultrasound, magnetic resonance imaging time-intensity curves and the Victorian Institute of Sport Assessment-Achilles questionnaire): a pilot study. *Skeletal Radiol*. 2010;39:509-521. <https://doi.org/10.1007/s00256-009-0772-0>
163. Rickaby R, El Khoury L, Ribbans WJ, Raleigh SM. Variation within three apoptosis associated genes as potential risk factors for Achilles tendinopathy in a British based case-control cohort. *Gene*. 2015;571:167-171. <https://doi.org/10.1016/j.gene.2015.06.010>
164. Rolf C, Movin T. Etiology, histopathology, and outcome of surgery in achillodynia. *Foot Ankle Int*. 1997;18:565-569. <https://doi.org/10.1177/107110079701800906>
165. Rompe JD, Furia J, Maffulli N. Eccentric loading versus eccentric loading plus shock-wave treatment for midportion Achilles tendinopathy: a randomized controlled trial. *Am J Sports Med*. 2009;37:463-470. <https://doi.org/10.1177/0363546508326983>
166. Rompe JD, Furia JP, Maffulli N. Mid-portion Achilles tendinopathy - current options for treatment. *Disabil Rehabil*. 2008;30:1666-1676. <https://doi.org/10.1080/09638280701785825>
167. Rompe JD, Nafe B, Furia JP, Maffulli N. Eccentric loading, shock-wave treatment, or a wait-and-see policy for tendinopathy of the main body of tendo Achillis: a randomized controlled trial. *Am J Sports Med*. 2007;35:374-383. <https://doi.org/10.1177/0363546506295940>
168. Rowe V, Hemmings S, Barton C, Malliaras P, Maffulli N, Morrissey D. Conservative management of midportion Achilles tendinopathy: a mixed methods study, integrating systematic review and clinical reasoning. *Sports Med*. 2012;42:941-967. <https://doi.org/10.2165/11635410-000000000-00000>
169. Sadoghi P, Rosso C, Valderrabano V, Leithner A, Vavken P. The role of platelets in the treatment of Achilles tendon injuries. *J Orthop Res*. 2013;31:111-118. <https://doi.org/10.1002/jor.22199>
170. Sanders TG, Rathur SK. Impingement syndromes of the ankle. *Magn Reson Imaging Clin N Am*. 2008;16:29-38. <https://doi.org/10.1016/j.mric.2008.02.005>
171. Saunders CJ, van der Merwe L, Cook J, Handley CJ, Collins M, September AV. Extracellular matrix proteins interact with cell-signaling pathways in modifying risk of Achilles tendinopathy. *J Orthop Res*. 2015;33:898-903. <https://doi.org/10.1002/jor.22820>
172. Saunders CJ, Van Der Merwe L, Cook J, Handley CJ, Collins M, September AV. Variants within the COMP and THBS2 genes are not associated with Achilles tendinopathy in a case-control study of South African and Australian populations. *J Sports Sci*. 2014;32:92-100. <https://doi.org/10.1080/02640414.2013.807351>
173. Saunders CJ, van der Merwe L, Posthumus M, et al. Investigation of variants within the COL27A1 and TNC genes and Achilles tendinopathy in two populations. *J Orthop Res*. 2013;31:632-637. <https://doi.org/10.1002/jor.22278>
174. Saxena A, Ramdath S, Jr., O'Halloran P, Gerdesmeyer L, Gollwitzer H. Extra-corporeal pulsed-activated therapy ("EPAT" sound wave) for Achilles tendinopathy: a prospective study. *J Foot Ankle Surg*. 2011;50:315-319. <https://doi.org/10.1053/j.jfas.2011.01.003>
175. Scholes M, Stadler S, Connell D, et al. Men with unilateral Achilles tendinopathy have impaired balance on the symptomatic side. *J Sci Med Sport*. 2018;21:479-482. <https://doi.org/10.1016/j.jsams.2017.09.594>
176. Scott RT, Hyer CF, Granata A. The correlation of Achilles tendinopathy and body mass index. *Foot Ankle Spec*. 2013;6:283-285. <https://doi.org/10.1177/1938640013490019>
177. Semciw A, Neate R, Pizzari T. Running related gluteus medius function in health and injury: a systematic review with meta-analysis. *J Electromyogr Kinesiol*. 2016;30:98-110. <https://doi.org/10.1016/j.jelekin.2016.06.005>
178. Sengkerij PM, de Vos RJ, Weir A, van Weelde BJ, Tol JL. Interobserver reliability of neovascularization score using power Doppler ultrasonography in midportion Achilles tendinopathy. *Am J Sports Med*. 2009;37:1627-1631. <https://doi.org/10.1177/0363546509332255>
179. September AV, Cook J, Handley CJ, van der Merwe L, Schwellnus MP, Collins M. Variants within the COL5A1 gene are associated with Achilles tendinopathy in two populations. *Br J Sports Med*. 2009;43:357-365. <https://doi.org/10.1136/bjsm.2008.048793>
180. September AV, Nell EM, O'Connell K, et al. A pathway-based approach investigating the genes encoding interleukin-1 β , interleukin-6 and the interleukin-1 receptor antagonist provides new insight into the genetic susceptibility of Achilles tendinopathy. *Br J Sports Med*. 2011;45:1040-1047. <https://doi.org/10.1136/bjsm.2010.076760>
181. Shultz S, Olszewski A, Ramsey O, Schmitz M, Wyatt V, Cook C. A systematic review of outcome tools used to measure lower leg conditions. *Int J Sports Phys Ther*. 2013;8:838-848.
182. Silbernagel KG, Brorsson A, Lundberg M. The majority of patients with Achilles tendinopathy recover fully when treated with exercise alone: a 5-year follow-up. *Am J Sports Med*. 2011;39:607-613. <https://doi.org/10.1177/0363546510384789>
183. Sobhani S, Dekker R, Postema K, Dijkstra PU. Epidemiology of ankle and foot overuse injuries in sports: a systematic review. *Scand J Med Sci Sports*. 2013;23:669-686. <https://doi.org/10.1111/j.1600-0838.2012.01509.x>
184. Sobrino FJ, de la Cuadra C, Guillén P. Overuse injuries in professional ballet: injury-based differences among ballet disciplines. *Orthop J Sports Med*. 2015;3:2325967115590114. <https://doi.org/10.1177/2325967115590114>
185. Spang C, Alfredson H, Ferguson M, Roos B, Bagge J, Forsgren S. The plantaris tendon in association with mid-portion Achilles tendinosis - tendinosis-like morphological features and presence of a non-neuronal cholinergic system. *Histol Histopathol*. 2013;28:623-632. <https://doi.org/10.14670/HH-28.623>
186. Spang C, Harandi VM, Alfredson H, Forsgren S. Marked innervation but also signs of nerve degeneration in between the Achilles and plantaris tendons and presence of innervation within the plantaris tendon in midportion Achilles tendinopathy. *J Musculoskelet Neuronal Interact*. 2015;15:197-206.
187. Stecco A, Busoni F, Stecco C, et al. Comparative ultrasonographic evaluation of the Achilles paratenon in symptomatic and asymptomatic subjects: an imaging study. *Surg Radiol Anat*. 2015;37:281-285. <https://doi.org/10.1007/s00276-014-1338-y>
188. Steinberg N, Dar G, Dunlop M, Gaida JE. The relationship of hip muscle performance to leg, ankle and foot injuries: a systematic review. *Phys Sportsmed*. 2017;45:49-63. <https://doi.org/10.1080/0091384720171280370>
189. Stephenson AL, Wu W, Cortes D, Rochon PA. Tendon injury and fluoroquinolone use: a systematic review. *Drug Saf*. 2013;36:709-721. <https://doi.org/10.1007/s40264-013-0089-8>
190. Stevens M, Tan CW. Effectiveness of the Alfredson protocol compared with a lower repetition-volume protocol for midportion Achilles tendinopathy: a randomized controlled trial. *J Orthop Sports Phys Ther*. 2014;44:59-67. <https://doi.org/10.2519/jospt.2014.4720>
191. Sunding K, Fahlström M, Werner S, Forsblad M, Willberg L. Evaluation of Achilles and patellar tendinopathy with greyscale ultrasound and colour

Doppler: using a four-grade scale. *Knee Surg Sports Traumatol Arthrosc.* 2016;24:1988-1996. <https://doi.org/10.1007/s00167-014-3270-4>

192. Sussmilch-Leitch SP, Collins NJ, Bialocerkowski AE, Warden SJ, Crossley KM. Physical therapies for Achilles tendinopathy: systematic review and meta-analysis. *J Foot Ankle Res.* 2012;5:15. <https://doi.org/10.1186/1757-1146-5-15>
193. Syha R, Springer F, Würslin C, et al. Tendinopathy of the Achilles tendon: volume assessed by automated contour detection in submillimeter isotropic 3-dimensional magnetic resonance imaging data sets recorded at a field strength of 3 T. *J Comput Assist Tomogr.* 2015;39:250-256. <https://doi.org/10.1097/RCT.0000000000000203>
194. Taylor J, Dunkerley S, Silver D, et al. Extracorporeal shockwave therapy (ESWT) for refractory Achilles tendinopathy: a prospective audit with 2-year follow up. *Foot (Edinb).* 2016;26:23-29. <https://doi.org/10.1016/j.foot.2015.08.007>
195. Tompra N, van Dieën JH, Coppieters MW. Central pain processing is altered in people with Achilles tendinopathy. *Br J Sports Med.* 2016;50:1004-1007. <https://doi.org/10.1136/bjsports-2015-095476>
196. Tumilty S, Mani R, Baxter GD. Photobiomodulation and eccentric exercise for Achilles tendinopathy: a randomized controlled trial. *Lasers Med Sci.* 2016;31:127-135. <https://doi.org/10.1007/s10103-015-1840-4>
197. Tumilty S, McDonough S, Hurley DA, Baxter GD. Clinical effectiveness of low-level laser therapy as an adjunct to eccentric exercise for the treatment of Achilles' tendinopathy: a randomized controlled trial. *Arch Phys Med Rehabil.* 2012;93:733-739. <https://doi.org/10.1016/j.apmr.2011.08.049>
198. Unlu MC, Kivrak A, Kayaalp ME, Birsol O, Akgun I. Peritendinous injection of platelet-rich plasma to treat tendinopathy: a retrospective review. *Acta Orthop Traumatol Turc.* 2017;51:482-487. <https://doi.org/10.1016/j.aott.2017.10.003>
199. van der Plas A, de Jonge S, de Vos RJ, et al. A 5-year follow-up study of Alfredson's heel-drop exercise programme in chronic midportion Achilles tendinopathy. *Br J Sports Med.* 2012;46:214-218. <https://doi.org/10.1136/bjsports-2011-090035>
200. Van Ginckel A, Thijs Y, Hesar NG, et al. Intrinsic gait-related risk factors for Achilles tendinopathy in novice runners: a prospective study. *Gait Posture.* 2009;29:387-391. <https://doi.org/10.1016/j.gaitpost.2008.10.058>
201. van Schie HT, de Vos RJ, de Jonge S, et al. Ultrasonographic tissue characterisation of human Achilles tendons: quantification of tendon structure through a novel non-invasive approach. *Br J Sports Med.* 2010;44:1153-1159. <https://doi.org/10.1136/bjsm.2009.061010>
202. Vaughn NH, Stepanyan H, Gallo RA, Dhawan A. Genetic factors in tendon injury: a systematic review of the literature. *Orthop J Sports Med.* 2017;5:2325967117724416. <https://doi.org/10.1177/2325967117724416>
203. Verrall G, Schofield S, Brustad T. Chronic Achilles tendinopathy treated with eccentric stretching program. *Foot Ankle Int.* 2011;32:843-849. <https://doi.org/10.3113/FAI.2011.0843>
204. Wang HK, Lin KH, Wu YK, Chi SC, Shih TT, Huang YC. Evoked spinal reflexes and force development in elite athletes with middle-portion Achilles tendinopathy. *J Orthop Sports Phys Ther.* 2011;41:785-794. <https://doi.org/10.2519/jospt.2011.3564>
205. Wetke E, Johannsen F, Langberg H. Achilles tendinopathy: a prospective study on the effect of active rehabilitation and steroid injections in a clinical setting. *Scand J Med Sci Sports.* 2015;25:e392-e399. <https://doi.org/10.1111/sms.12326>
206. Wheeler PC, Mahadevan D, Bhatt R, Bhatia M. A comparison of two different high-volume image-guided injection procedures for patients with chronic noninsertional Achilles tendinopathy: a pragmatic retrospective cohort study. *J Foot Ankle Surg.* 2016;55:976-979. <https://doi.org/10.1053/j.jfas.2016.04.017>
207. Woods C, Hawkins R, Hulse M, Hodson A. The Football Association Medical Research Programme: an audit of injuries in professional football—analysis of preseason injuries. *Br J Sports Med.* 2002;36:436-441; discussion 441. <https://doi.org/10.1136/bjsm.36.6.436>
208. Yang X, Coleman DP, Pugh ND, Nokes LD. A novel 3-D power Doppler ultrasound approach to the quantification of Achilles tendon neovascularity. *Ultrasound Med Biol.* 2011;37:1046-1055. <https://doi.org/10.1016/j.ultrasmedbio.2011.04.008>
209. Yang X, Coleman DP, Pugh ND, Nokes LD. The volume of the neovascularity and its clinical implications in Achilles tendinopathy. *Ultrasound Med Biol.* 2012;38:1887-1895. <https://doi.org/10.1016/j.ultrasmedbio.2012.07.002>
210. Yang X, Pugh ND, Coleman DP, Nokes LD. Are Doppler studies a useful method of assessing neovascularization in human Achilles tendinopathy? A systematic review and suggestions for optimizing machine settings. *J Med Eng Technol.* 2010;34:365-372. <https://doi.org/10.3109/03091902.2010.497892>
211. Yasui Y, Tonogai I, Rosenbaum AJ, Shimozone Y, Kawano H, Kennedy JG. The risk of Achilles tendon rupture in the patients with Achilles tendinopathy: healthcare database analysis in the United States. *Biomed Res Int.* 2017;2017:7021862. <https://doi.org/10.1155/2017/7021862>
212. Yelland MJ, Sweeting KR, Lyftogt JA, Ng SK, Scuffham PA, Evans KA. Prolotherapy injections and eccentric loading exercises for painful Achilles tendinosis: a randomised trial. *Br J Sports Med.* 2011;45:421-428. <https://doi.org/10.1136/bjsm.2009.057968>
213. Yeo A, Kendall N, Jayaraman S. Ultrasound-guided dry needling with percutaneous paratenon decompression for chronic Achilles tendinopathy. *Knee Surg Sports Traumatol Arthrosc.* 2016;24:2112-2118. <https://doi.org/10.1007/s00167-014-3458-7>
214. Yu J. Comparison of lower limb muscle activity during eccentric and concentric exercises in runners with Achilles tendinopathy. *J Phys Ther Sci.* 2014;26:1351-1353. <https://doi.org/10.1589/jpts.26.1351>
215. Zhang BM, Zhong LW, Xu SW, Jiang HR, Shen J. Acupuncture for chronic Achilles tendinopathy: a randomized controlled study. *Chin J Integr Med.* 2013;19:900-904. <https://doi.org/10.1007/s11655-012-1218-4>



MORE INFORMATION
WWW.JOSPT.ORG

APPENDIX A

SEARCH STRATEGIES FOR ALL DATABASES SEARCHED

Limits: 2009 to present (05/11/2015); human; English (published CPG search included articles published from February 1, 2009 to present)

PubMed

History: 05/12/2015

Search	Add to Builder	Query	Items Found, n	Time
#21	Add	Search (#18 not #2) Filters: Publication date from 2009/01/01; English	601	12:50:43
#19	Add	Search (#18 not #2)	1424	12:50:43
#18	Add	Search (#16 or #17)	1515	12:49:05
#17	Add	Search ("achilles tendon"[MeSH Terms] OR ("achilles"[All Fields] AND "tendon"[All Fields]) OR "achilles tendon"[All Fields] OR "achilles"[All Fields]) AND ("tendinopathy"[MeSH Terms] OR "tendinopathy"[All Fields])	1425	11:31:17
#16	Add	Search ("achilles tendon"[MeSH Terms] OR ("achilles"[All Fields] AND "tendon"[All Fields]) OR "achilles tendon"[All Fields] OR "achilles"[All Fields]) AND ("tendinopathy"[MeSH Terms] OR "tendinopathy"[All Fields] OR "tendinitis"[All Fields])	1515	11:30:50
#2	Add	Search (animal not human)	3735987	09:46:42

Cochrane

Search Name: Achilles CPG Cochrane 05122015

Date Run: 12/05/15 16:09:42.256

Description: ID

Search hits: #1. achilles and (tendinitis or tendino* or tendono* or paratendino* or paratendono* or pantendino* or Pantendono*);ti,ab,kw

Publication Year from 2009 to 2015 (Word variations have been searched)

CINAHL

Tuesday, May 12, 2015 11:48:18 AM

Number	Query	Limiters/Expanders	Last Run Via
S4	S1 OR S2	Limiters - Published Date: 20090101-; English Language; Human Search modes - Find all my search terms	Interface - EBSCOhost Research Databases Search Screen - Advanced Search Database - CINAHL
S3	S1 OR S2	Search modes - Find all my search terms	Interface - EBSCOhost Research Databases Search Screen - Advanced Search Database - CINAHL
S2	achilles AND tendono* OR tendino* OR pantendino* OR pantendono* OR paratendino* OR paratendono*	Search modes - Find all my search terms	Interface - EBSCOhost Research Databases Search Screen - Advanced Search Database - CINAHL
S1	(MH "Achilles Tendinopathy")	Search modes - Find all my search terms	Interface - EBSCOhost Research Databases Search Screen - Advanced Search Database - CINAHL

APPENDIX A

PEDro

Achilles AND tend* from 2009 forward

"Update" search strategies (May 15, 2015-April 12, 2016)

PEDro search run on 4/12/2016 and Update searches from 4/12/2016 to 11/18/2017

Achilles AND tend* from 5/13/2015 forward

Achilles AND tend* from 4/12/2016 forward

PubMed Search

Run 4/12/2016

Search	Query
#5	Search (#2 NOT #1) AND 2015/05/12:2016 [edat] Filters: English
#4	Search (#2 NOT #1) Filters: English
#3	Search (#2 NOT #1)
#2	Search (("achilles tendon"[MeSH Terms] OR ("achilles"[All Fields] AND "tendon"[All Fields]) OR "achilles tendon"[All Fields] OR "achilles"[All Fields]) AND ("tendinopathy"[MeSH Terms] OR "tendinopathy"[All Fields] OR "tendinitis"[All Fields]))
#1	Search animal NOT human

Update searches from 4/12/2016 to 11/18/2017

PubMed

Search	Query	Items Found, n
#5	Search (#2 NOT #1) Filters: Publication date from 2016/04/01 to 2017/11/18; English	245
#4	Search (#2 NOT #1) Filters: English	1617
#3	Search (#2 NOT #1)	1816
#2	Search (("achilles tendon"[MeSH Terms] OR ("achilles"[All Fields] AND "tendon"[All Fields]) OR "achilles tendon"[All Fields] OR "achilles"[All Fields]) AND ("tendinopathy"[MeSH Terms] OR "tendinopathy"[All Fields] OR "tendinitis"[All Fields]))	1930
#1	Search animal NOT human	4167941

CINAHL Search

Run on 4/12/2016

Number	Query	Limiters/Expanders
S3	(S1 OR S2) AND EM 20150513-	Limiters - English Language; Human Search modes - Find all my search terms
S2	achilles AND (tendono* OR tendino* OR pantendino* OR pantendono* OR paratendino* OR paratendono*)	Search modes - Find all my search terms
S1	(MH "Achilles Tendinopathy")	Search modes - Find all my search terms

CINAHL

(Updated Searches From 4/12/2016 to 11/18/2017)

Search	Query	Items Found, n
S3	(S1 OR S2) Limiters - Published Date: 20160401-20171131; Language: English Search modes - Find all my search terms	87
S2	achilles AND (tendono* OR tendino* OR pantendino* OR pantendono* OR paratendino* OR paratendono*) Search modes - Find all my search terms	874
S1	(MH "Achilles Tendinopathy") Search modes - Find all my search terms	544

APPENDIX A

Cochrane Search

Run on 4/12/2016

achilles and (tendinitis or tendino* or tendono* or paratendino* or paratendono* or pantendino* or Pantendono*):ti,ab,kw Publication Year from 2015 to 2016

Cochrane

(Updated Searches From 4/12/2016 to 11/18/2017)

Search	Query	Items Found, n
	achilles and (tendinitis or tendino* or tendono* or paratendino* or paratendono* or pantendino* or Pantendono*):ti,ab,kw Publication Year from 2016 to 2017	1 review, 35 trials

APPENDIX B

SEARCH RESULTS

Database	Platform	Original Date Conducted	Original Results, n	2016 Update Date Conducted	2016 Update Results, n	2017 Update Date Conducted	2017 Update Results, n
MEDLINE	PubMed	5/12/2015	601	4/12/2016 (from Entrez date 5/13/2015)	112	11/18/2017 (from Entrez date 4/12/2017)	245
Cochrane Library	Wiley	5/12/2015	69 Cochrane reviews (4) Other reviews (12) Trials (52) Economic evaluations (1)	4/12/2016	10	11/18/2017 (year 2016-2017)	1 review 35 trials
CINAHL	EBSCO	5/12/2015	392	4/12/2016	9	11/18/2017	87
PEDro	CEBP	5/12/2015	45	4/12/2016 (new records added from May 13, 2015 to current)	9	11/18/2017	9
Total			1107		140		377
Total with duplicates removed			993 (duplicates, 114)		129 (duplicates, 11)		287 (duplicates, 90)

APPENDIX C

ARTICLE INCLUSION AND EXCLUSION CRITERIA**I. Article Characteristics**

Include:

- English
- Published from 2009 to present (published CPG search included articles published up to February 1, 2009)
- Articles reporting analysis of data: systematic reviews, meta-analyses, experimental and quasi-experimental, cohort, case series ($n \geq 10$), and cross-sectional studies

Exclude:

- Study protocols
- Abstracts, press reports, newsletters, editorial letters
- Articles published in non-peer-reviewed publications (eg, theses)
- Case reports (1 patient per case) and case series with fewer than 10 patients

II. Patient/Participant Characteristics

Include:

- Studies using data from humans
- Participants over 16 years of age (if mixed, the mean should be over 16 years)
- Participants with Achilles tendinitis, tendinopathy, tendinosis
- If the article reports on Achilles tendinopathy along with other conditions, then there must be at least enough patients (greater than 15 in each group) with Achilles tendinopathy AND the results must be reported for Achilles tendinopathy separately

Exclude:

- Articles on healthy/normal participants

III. Topics Included**A. For evidence update**

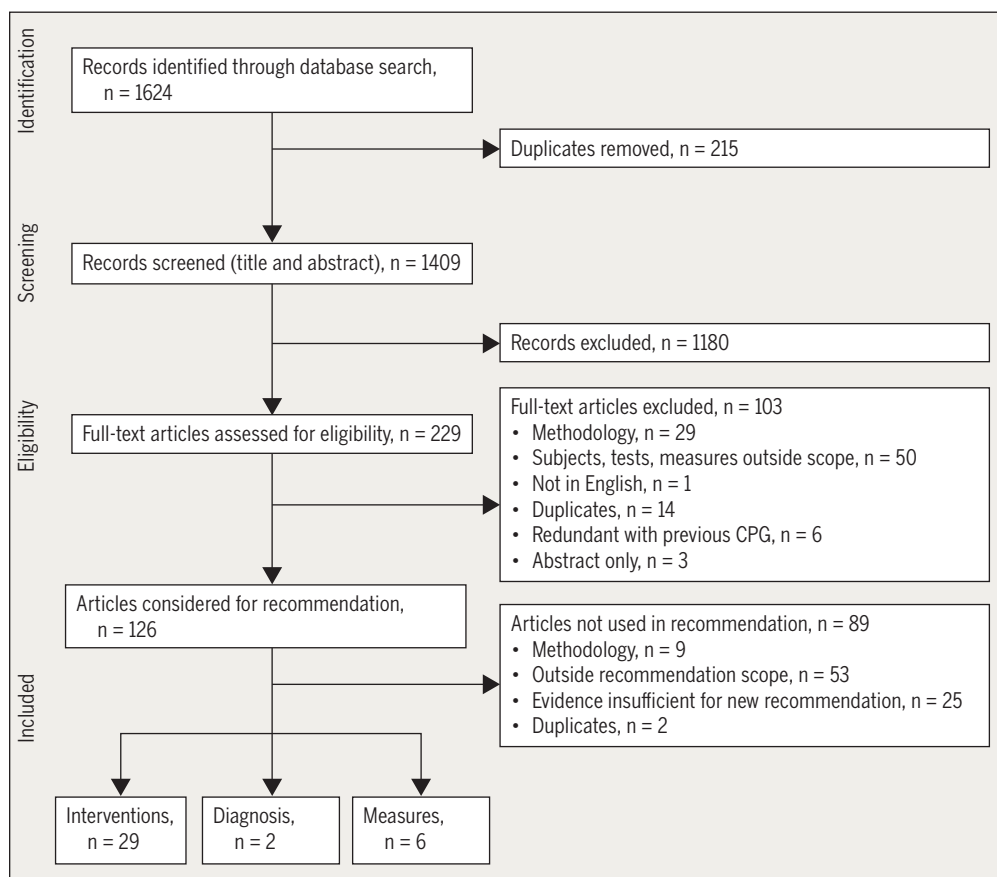
- Prevalence
- Pathoanatomic features: the functional anatomy of the ankle and foot relevant to Achilles tendinopathy
- Risk factors
 - Intrinsic (eg, decreased dorsiflexion range of motion, subtalar motion, plantar flexion strength, pronation, and health conditions/comorbidities such as obesity, hypertension, hyperlipidemia, and diabetes)
 - Extrinsic (eg, training characteristics, environmental factors, equipment-related factors)
- Prognosis
- Imaging studies

B. For formal systematic review

- Classification systems, including but not limited to Curwin and Stanish, Nirschl Pain Phase Scale of Athletic Overuse Injuries, and Puffer and Zachazewski scale
- Tests and measures for diagnosis of Achilles tendinopathy within the scope of physical therapist practice, including but not limited to Achilles tendon palpation test, plantar flexion range of motion, unilateral heel-raise test, the arc sign, Victorian Institute of Sport Assessment-Achilles, Foot and Ankle Ability Measure, Royal London Hospital test
- Differential diagnosis, including but not limited to acute Achilles rupture, partial Achilles tear, retrocalcaneal bursitis, posterior ankle impingement, sural nerve neuroma or irritation, os trigonum syndrome, accessory soleus, Achilles tendon ossification, systemic inflammatory disease, and insertional Achilles tendinopathy
- Measurement properties of outcome measures relevant for Achilles tendinopathy, including but not limited to measures assessing:
 - Body structures and function
 - Truncated arch height ratio
 - Arc sign
 - Royal London Hospital test
 - Forefoot alignment
 - Achilles tendon palpation test
 - Pain
 - Range of motion (dorsiflexion, plantar flexion, inversion, eversion)
 - Plantar flexion strength
 - Plantar flexion endurance
 - Activity (eg, the Silbernagel battery)
 - Participation
- Interventions within the scope of practice of physical therapists, including but not limited to:
 - Eccentric loading or other exercise
 - Low-level laser therapy
 - Iontophoresis
 - Stretching
 - Foot orthoses
 - Manual therapy
 - Taping
 - Heel lifts
 - Shockwave

APPENDIX D

FLOW DIAGRAM OF ARTICLES LEADING TO RECOMMENDATIONS



APPENDIX E

ARTICLES INCLUDED IN RECOMMENDATIONS
BY TOPIC

Diagnosis

- Hutchison AM, Evans R, Bodger O, et al. What is the best clinical test for Achilles tendinopathy? *Foot Ankle Surg.* 2013;19:112-117. <https://doi.org/10.1016/j.fas.2012.12.006>
- Reiman M, Burgi C, Strube E, et al. The utility of clinical measures for the diagnosis of Achilles tendon injuries: a systematic review with meta-analysis. *J Athl Train.* 2014;49:820-829. <https://doi.org/10.4085/1062-6050-49.3.36>

Examination

Outcome Measures – Activity Limitations/Self-Reported Measures

- Dogramaci Y, Kalaci A, Küçükbaş N, Inandı T, Esen E, Yanat AN. Validation of the VISA-A questionnaire for Turkish language: the VISA-A-Tr study. *Br J Sports Med.* 2011;45:453-455. <https://doi.org/10.1136/bjsm.2009.060236>
- Iversen JV, Bartels EM, Jørgensen JE, et al. Danish VISA-A questionnaire with validation and reliability testing for Danish-speaking Achilles tendinopathy patients. *Scand J Med Sci Sports.* 2016;26:1423-1427. <https://doi.org/10.1111/sms.12576>
- Kaux JF, Delvaux F, Oppong-Kyei J, et al. Validity and reliability of the French translation of the VISA-A questionnaire for Achilles tendinopathy. *Disabil Rehabil.* 2016;38:2593-2599. <https://doi.org/10.3109/09638288.2016.1138553>
- Mehta SP, Fulton A, Quach C, Thistle M, Toledo C, Evans NA. Measurement properties of the Lower Extremity Functional Scale: a systematic review. *J Orthop Sports Phys Ther.* 2016;46:200-216. <https://doi.org/10.2519/jospt.2016.6165>
- Shultz S, Olszewski A, Ramsey O, Schmitz M, Wyatt V, Cook C. A systematic review of outcome tools used to measure lower leg conditions. *Int J Sports Phys Ther.* 2013;8:838-848.

Activity Limitations – Physical Performance Measures

- MacDermid JC, Silbernagel KG. Outcome evaluation in tendinopathy: foundations of assessment and a summary of selected measures. *J Orthop Sports Phys Ther.* 2015;45:950-964. <https://doi.org/10.2519/jospt.2015.6054>

INTERVENTIONS

Exercise

- Beyer R, Kongsgaard M, Hougs Kjaer B, Øhlenschläger T, Kjaer M, Magnusson SP. Heavy slow resistance versus eccentric training as treatment for Achilles tendinopathy: a randomized controlled trial. *Am J Sports Med.* 2015;43:1704-1711. <https://doi.org/10.1177/0363546515584760>
- de Jonge S, de Vos RJ, Weir A, et al. One-year follow-up of platelet-rich plasma treatment in chronic Achilles tendinopathy: a double-blind randomized placebo-controlled trial. *Am J Sports Med.* 2011;39:1623-1629. <https://doi.org/10.1177/0363546511404877>
- de Vos RJ, Heijboer MP, Weinans H, Verhaar JA, van Schie JT. Tendon structure's lack of relation to clinical outcome after eccentric exercises in chronic midportion Achilles tendinopathy. *J Sport Rehabil.* 2012;21:34-43. <https://doi.org/10.1123/jsr.21.1.34>
- de Vos RJ, Weir A, Tol JL, Verhaar JA, Weinans H, van Schie HT. No effects of PRP on ultrasonographic tendon structure and neovascularisation in chronic midportion Achilles tendinopathy. *Br J Sports Med.* 2011;45:387-392. <https://doi.org/10.1136/bjsm.2010.076398>
- de Vos RJ, Weir A, van Schie HT, et al. Platelet-rich plasma injection for chronic Achilles tendinopathy: a randomized controlled trial. *JAMA.* 2010;303:144-149. <https://doi.org/10.1001/jama.2009.1986>
- Frizziero A, Trainito S, Oliva F, Nicoli Aldini N, Masiero S, Maffulli N. The role of eccentric exercise in sport injuries rehabilitation. *Br Med Bull.* 2014;110:47-75. <https://doi.org/10.1093/bmb/ldu006>
- Habets B, van Cingel RE. Eccentric exercise training in chronic midportion Achilles tendinopathy: a systematic review on different protocols. *Scand J Med Sci Sports.* 2015;25:3-15. <https://doi.org/10.1111/sms.12208>
- Magnussen RA, Dunn WR, Thomson AB. Nonoperative treatment of midportion Achilles tendinopathy: a systematic review. *Clin J Sport Med.* 2009;19:54-64. <https://doi.org/10.1097/JSM.0b013e31818ef090>
- Malliaras P, Barton CJ, Reeves ND, Langberg H. Achilles and patellar tendinopathy loading programmes: a systematic review comparing clinical outcomes and identifying potential mechanisms for effectiveness. *Sports Med.* 2013;43:267-286. <https://doi.org/10.1007/s40279-013-0019-z>
- Pearson J, Rowlands D, Highet R. Autologous blood injection to treat Achilles tendinopathy? A randomized controlled trial. *J Sport Rehabil.* 2012;21:218-224. <https://doi.org/10.1123/jsr.21.3.218>
- Ram R, Meeuwisse W, Patel C, Wiseman DA, Wiley JP. The limited effectiveness of a home-based eccentric training for treatment of Achilles tendinopathy. *Clin Invest Med.* 2013;36:E197-E206.
- Rompe JD, Furia J, Maffulli N. Eccentric loading versus eccentric loading plus shock-wave treatment for midportion Achilles tendinopathy: a randomized controlled trial. *Am J Sports Med.* 2009;37:463-470. <https://doi.org/10.1177/0363546508326983>
- Rowe V, Hemmings S, Barton C, Malliaras P, Maffulli N, Morrissey D. Conservative management of midportion Achilles tendinopathy: a mixed methods study, integrating systematic review and clinical reasoning. *Sports Med.* 2012;42:941-967. <https://doi.org/10.2165/11635410-000000000-00000>
- Stevens M, Tan CW. Effectiveness of the Alfredson protocol compared with a lower repetition-volume protocol for midportion Achilles tendinopathy: a randomized controlled trial. *J Orthop Sports Phys Ther.* 2014;44:59-67. <https://doi.org/10.2519/jospt.2014.4720>
- Sussmilch-Leitch SP, Collins NJ, Bialocerkowski AE, Warden SJ, Crossley KM. Physical therapies for Achilles tendinopathy: systematic review and meta-analysis. *J Foot Ankle Res.* 2012;5:15. <https://doi.org/10.1186/1757-1146-5-15>

APPENDIX E

Tumilty S, Mani R, Baxter GD. Photobiomodulation and eccentric exercise for Achilles tendinopathy: a randomized controlled trial. *Lasers Med Sci*. 2016;31:127-135. <https://doi.org/10.1007/s10103-015-1840-4>

Tumilty S, McDonough S, Hurley DA, Baxter GD. Clinical effectiveness of low-level laser therapy as an adjunct to eccentric exercise for the treatment of Achilles' tendinopathy: a randomized controlled trial. *Arch Phys Med Rehabil*. 2012;93:733-739. <https://doi.org/10.1016/j.apmr.2011.08.049>

Yelland MJ, Sweeting KR, Lyftogt JA, Ng SK, Scuffham PA, Evans KA. Prolotherapy injections and eccentric loading exercises for painful Achilles tendinosis: a randomised trial. *Br J Sports Med*. 2011;45:421-428. <https://doi.org/10.1136/bjsm.2009.057968>

Zhang BM, Zhong LW, Xu SW, Jiang HR, Shen J. Acupuncture for chronic Achilles tendinopathy: a randomized controlled study. *Chin J Integr Med*. 2013;19:900-904. <https://doi.org/10.1007/s11655-012-1218-4>

Stretching

Verrall G, Schofield S, Brustad T. Chronic Achilles tendinopathy treated with eccentric stretching program. *Foot Ankle Int*. 2011;32:843-849. <https://doi.org/10.3113/FAI.2011.0843>

Neuromuscular Re-education

Azevedo LB, Lambert MI, Vaughan CL, O'Connor CM, Schwellnus MP. Biomechanical variables associated with Achilles tendinopathy in runners. *Br J Sports Med*. 2009;43:288-292. <https://doi.org/10.1136/bjsm.2008.053421>

Baur H, Müller S, Hirschmüller A, Cassel M, Weber J, Mayer F. Comparison in lower leg neuromuscular activity between runners with unilateral mid-portion Achilles tendinopathy and healthy individuals. *J Electromyogr Kinesiol*. 2011;21:499-505. <https://doi.org/10.1016/j.jelekin.2010.11.010>

Franettovich Smith MM, Honeywill C, Wyndow N, Crossley KM, Creaby MW. Neuromotor control of gluteal muscles in runners with Achilles tendinopathy. *Med Sci Sports Exerc*. 2014;46:594-599. <https://doi.org/10.1249/MSS.0000000000000133>

Manual Therapy

Cheatham SW, Lee M, Cain M, Baker R. The efficacy of instrument assisted soft tissue mobilization: a systematic review. *J Can Chiropr Assoc*. 2016;60:200-211.

Patient Education: Activity Modification

Silbernagel KG, Brorsson A, Lundberg M. The majority of patients with Achilles tendinopathy recover fully when treated with exercise alone: a 5-year follow-up. *Am J Sports Med*. 2011;39:607-613. <https://doi.org/10.1177/0363546510384789>

Patient Counseling

Rowe V, Hemmings S, Barton C, Malliaras P, Maffulli N, Morrissey D. Conservative management of midportion Achilles tendinopathy: a mixed methods study, integrating systematic review and clinical reasoning. *Sports Med*. 2012;42:941-967. <https://doi.org/10.2165/11635410-000000000-00000>

thy: a mixed methods study, integrating systematic review and clinical reasoning. *Sports Med*. 2012;42:941-967. <https://doi.org/10.2165/11635410-000000000-00000>

Silbernagel KG, Brorsson A, Lundberg M. The majority of patients with Achilles tendinopathy recover fully when treated with exercise alone: a 5-year follow-up. *Am J Sports Med*. 2011;39:607-613. <https://doi.org/10.1177/0363546510384789>

Night Splints

de Jonge S, de Vos RJ, Van Schie HT, Verhaar JA, Weir A, Tol JL. One-year follow-up of a randomised controlled trial on added splinting to eccentric exercises in chronic midportion Achilles tendinopathy. *Br J Sports Med*. 2010;44:673-677. <https://doi.org/10.1136/bjsm.2008.052142>

Sussmilch-Leitch SP, Collins NJ, Bialocerkowski AE, Warden SJ, Crossley KM. Physical therapies for Achilles tendinopathy: systematic review and meta-analysis. *J Foot Ankle Res*. 2012;5:15. <https://doi.org/10.1186/1757-1146-5-15>

Orthoses

Magnussen RA, Dunn WR, Thomson AB. Nonoperative treatment of midportion Achilles tendinopathy: a systematic review. *Clin J Sport Med*. 2009;19:54-64. <https://doi.org/10.1097/JSM.0b013e31818ef090>

Munteanu SE, Scott LA, Bonanno DR, et al. Effectiveness of customised foot orthoses for Achilles tendinopathy: a randomised controlled trial. *Br J Sports Med*. 2015;49:989-994. <https://doi.org/10.1136/bjsports-2014-093845>

Rowe V, Hemmings S, Barton C, Malliaras P, Maffulli N, Morrissey D. Conservative management of midportion Achilles tendinopathy: a mixed methods study, integrating systematic review and clinical reasoning. *Sports Med*. 2012;42:941-967. <https://doi.org/10.2165/11635410-000000000-00000>

Taping

Firth BL, Dingley P, Davies ER, Lewis JS, Alexander CM. The effect of kinesiotape on function, pain, and motoneuronal excitability in healthy people and people with Achilles tendinopathy. *Clin J Sport Med*. 2010;20:416-421. <https://doi.org/10.1097/JSM.0b013e3181f479b0>

Rowe V, Hemmings S, Barton C, Malliaras P, Maffulli N, Morrissey D. Conservative management of midportion Achilles tendinopathy: a mixed methods study, integrating systematic review and clinical reasoning. *Sports Med*. 2012;42:941-967. <https://doi.org/10.2165/11635410-000000000-00000>

Low-Level Laser Therapy

Hutchison AM, Pallister I, Evans RM, et al. Intense pulsed light treatment of chronic mid-body Achilles tendinopathy: a double blind randomised placebo-controlled trial. *Bone Joint J*. 2013;95-B:504-509. <https://doi.org/10.1302/0301-620X.95B4.30558>

Tumilty S, Mani R, Baxter GD. Photobiomodulation and eccentric

APPENDIX E

exercise for Achilles tendinopathy: a randomized controlled trial. *Lasers Med Sci.* 2016;31:127-135. <https://doi.org/10.1007/s10103-015-1840-4>

Tumilty S, McDonough S, Hurley DA, Baxter GD. Clinical effectiveness of low-level laser therapy as an adjunct to eccentric exercise for the treatment of Achilles' tendinopathy: a randomized controlled trial. *Arch Phys Med Rehabil.* 2012;93:733-739. <https://doi.org/10.1016/j.apmr.2011.08.049>

Dry Needling

Wheeler PC, Mahadevan D, Bhatt R, Bhatia M. A comparison of two different high-volume image-guided injection procedures for patients with chronic noninsertional Achilles tendinopathy: a pragmatic retrospective cohort study. *J Foot Ankle Surg.* 2016;55:976-979. <https://doi.org/10.1053/j.jfas.2016.04.017>

Yeo A, Kendall N, Jayaraman S. Ultrasound-guided dry needling with percutaneous paratenon decompression for chronic Achilles tendinopathy. *Knee Surg Sports Traumatol Arthrosc.* 2016;24:2112-2118. <https://doi.org/10.1007/s00167-014-3458-7>

APPENDIX F

LEVELS OF EVIDENCE TABLE*

Level	Intervention/ Prevention	Pathoanatomic/Risk/ Clinical Course/ Prognosis/Differential Diagnosis	Diagnosis/Diagnostic Accuracy	Prevalence of Condition/Disorder	Exam/Outcomes
I	Systematic review of high-quality RCTs High-quality RCT [†]	Systematic review of prospective cohort studies High-quality prospective cohort study [‡]	Systematic review of high-quality diagnostic studies High-quality diagnostic study [§] with validation	Systematic review, high- quality cross-sectional studies High-quality cross- sectional study	Systematic review of prospective cohort studies High-quality prospective cohort study
II	Systematic review of high-quality cohort studies High-quality cohort study [‡] Outcomes study or eco- logical study Lower-quality RCT [†]	Systematic review of retrospective cohort study Lower-quality prospec- tive cohort study High-quality retrospec- tive cohort study Consecutive cohort Outcomes study or eco- logical study	Systematic review of exploratory diagnostic studies or consecutive cohort studies High-quality exploratory diagnostic studies Consecutive retrospec- tive cohort	Systematic review of studies that allows relevant estimate Lower-quality cross- sectional study	Systematic review of lower-quality prospec- tive cohort studies Lower-quality prospec- tive cohort study
III	Systematic reviews of case-control studies High-quality case-control study Lower-quality cohort study	Lower-quality retrospec- tive cohort study High-quality cross- sectional study Case-control study	Lower-quality exploratory diagnostic studies Nonconsecutive retro- spective cohort	Local nonrandom study	High-quality cross- sectional study
IV	Case series	Case series	Case-control study		Lower-quality cross- sectional study
V	Expert opinion	Expert opinion	Expert opinion	Expert opinion	Expert opinion

Abbreviation: RCT, randomized clinical trial.

*Adapted from Phillips et al⁴⁹ (<http://www.cebm.net/index.aspx?o=1025>). See also APPENDIX G.

[†]High quality includes RCTs with greater than 80% follow-up, blinding, and appropriate randomization procedures.

[‡]High-quality cohort study includes greater than 80% follow-up.

[§]High-quality diagnostic study includes consistently applied reference standard and blinding.

^{||}High-quality prevalence study is a cross-sectional study that uses a local and current random sample or censuses.

*Weaker diagnostic criteria and reference standards, improper randomization, no blinding, and less than 80% follow-up may add bias and threats to validity.

APPENDIX G

PROCEDURES FOR ASSIGNING LEVELS OF EVIDENCE

- Level of evidence is assigned based on the study design using the Levels of Evidence table (**APPENDIX F**), assuming high quality (eg, for intervention, randomized clinical trial starts at level I)
- Study quality is assessed using the critical appraisal tool, and the study is assigned 1 of 4 overall quality ratings based on the critical appraisal results
- Level of evidence assignment is adjusted based on the overall quality rating:
 - High quality (high confidence in the estimate/results): study remains at assigned level of evidence (eg, if the randomized clinical trial is rated high quality, its final assignment is level I). High quality should include:
 - Randomized clinical trial with greater than 80% follow-up, blinding, and appropriate randomization procedures
 - Cohort study includes greater than 80% follow-up
 - Diagnostic study includes consistently applied reference standard and blinding
 - Prevalence study is a cross-sectional study that uses a local and current random sample or censuses
 - Acceptable quality (the study does not meet requirements for high quality and weaknesses limit the confidence in the accuracy of the estimate): downgrade 1 level
 - Based on critical appraisal results
 - Low quality: the study has significant limitations that substantially limit confidence in the estimate: downgrade 2 levels
 - Based on critical appraisal results
 - Unacceptable quality: serious limitations: exclude from consideration in the guideline
 - Based on critical appraisal results