

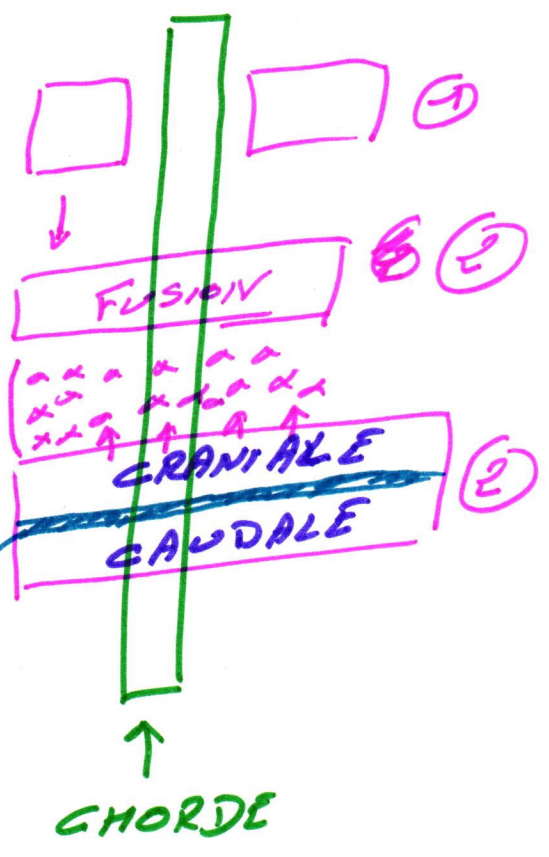
① SOTTITE




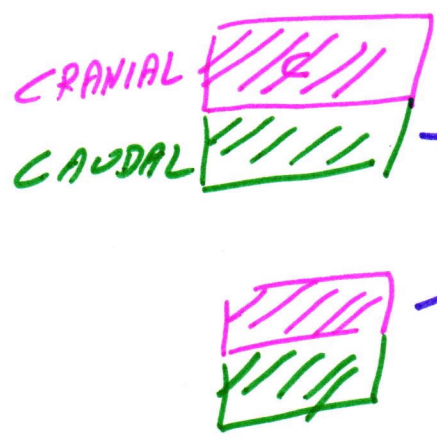
se detache

2. MEDIO VENTRALE (SCLEROTOPE)

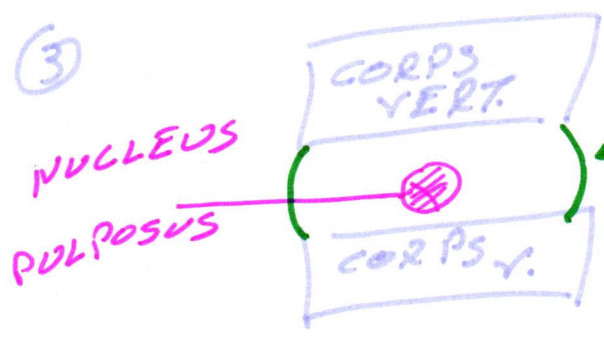
MESENCHY. ITATEUX  
Fissure de von Ebner



②



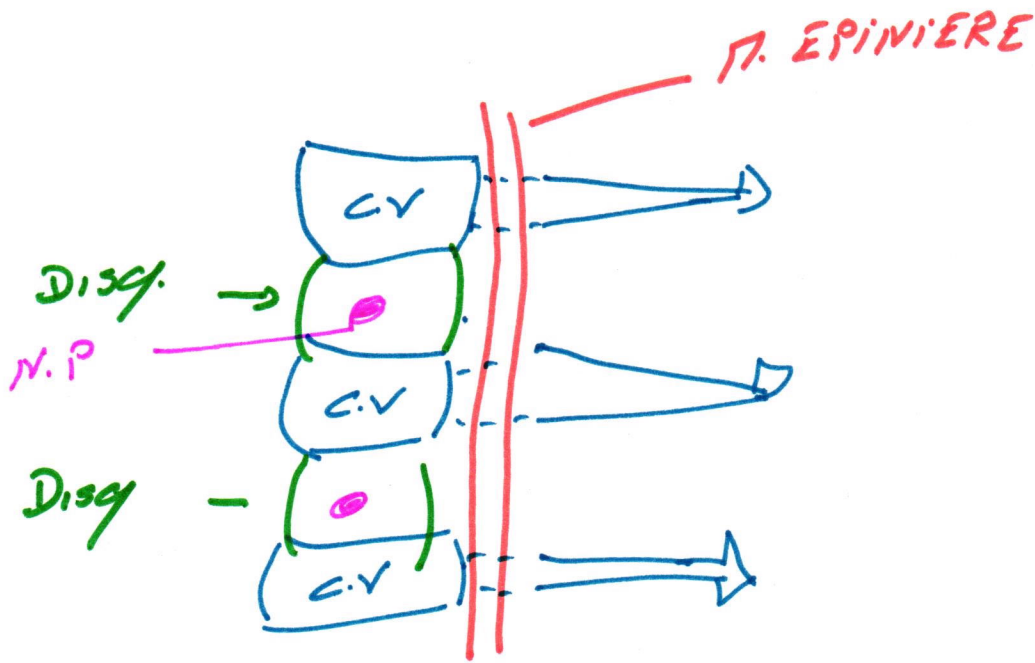
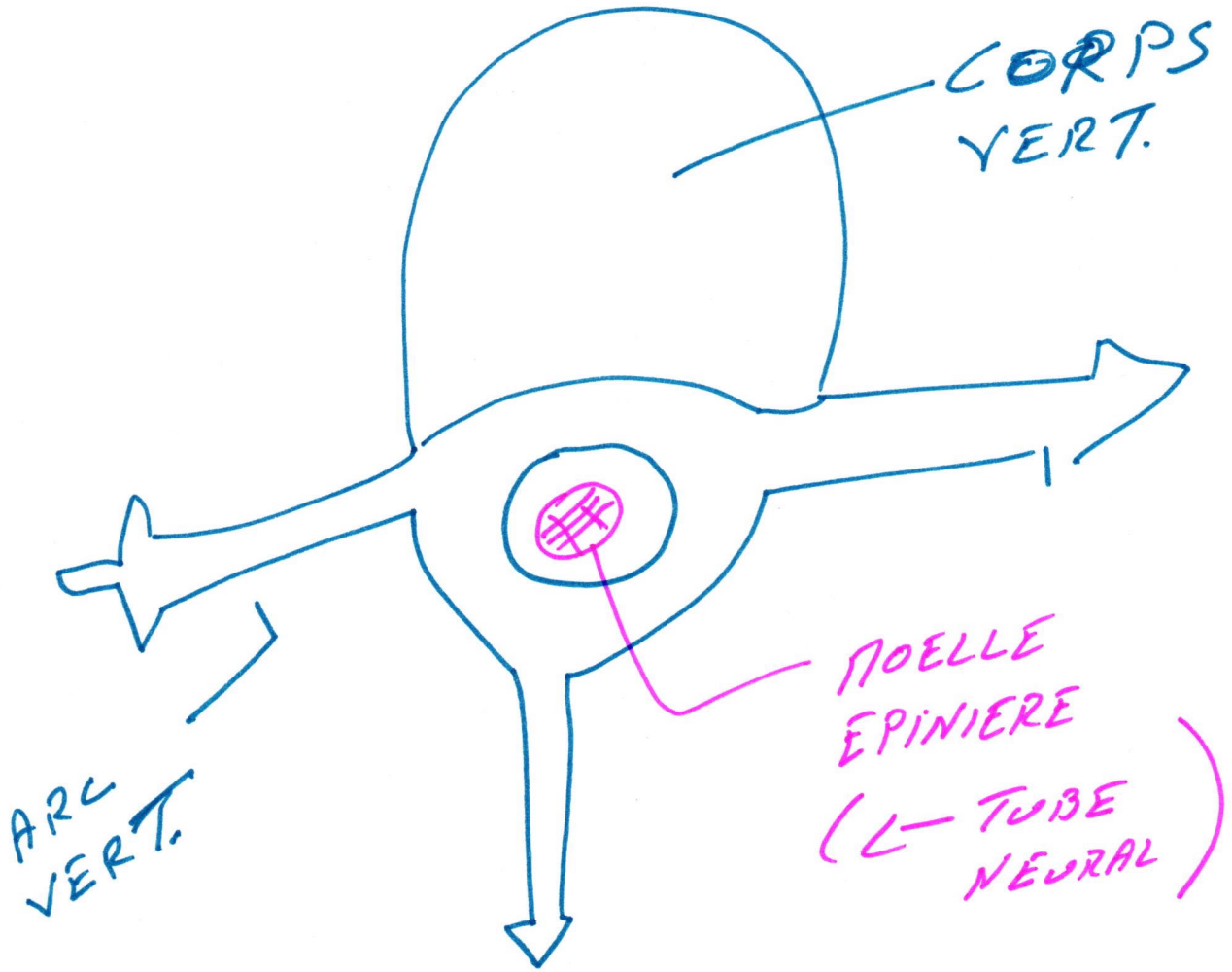
③



DISQUE INTER VERTEBRAL

(3)

II




π. Int  
|

π. P.A  
|

CHORDE  
|

NEPHRO  
TOTE



2 NEPHR.  
/ SOTITE

π. Int



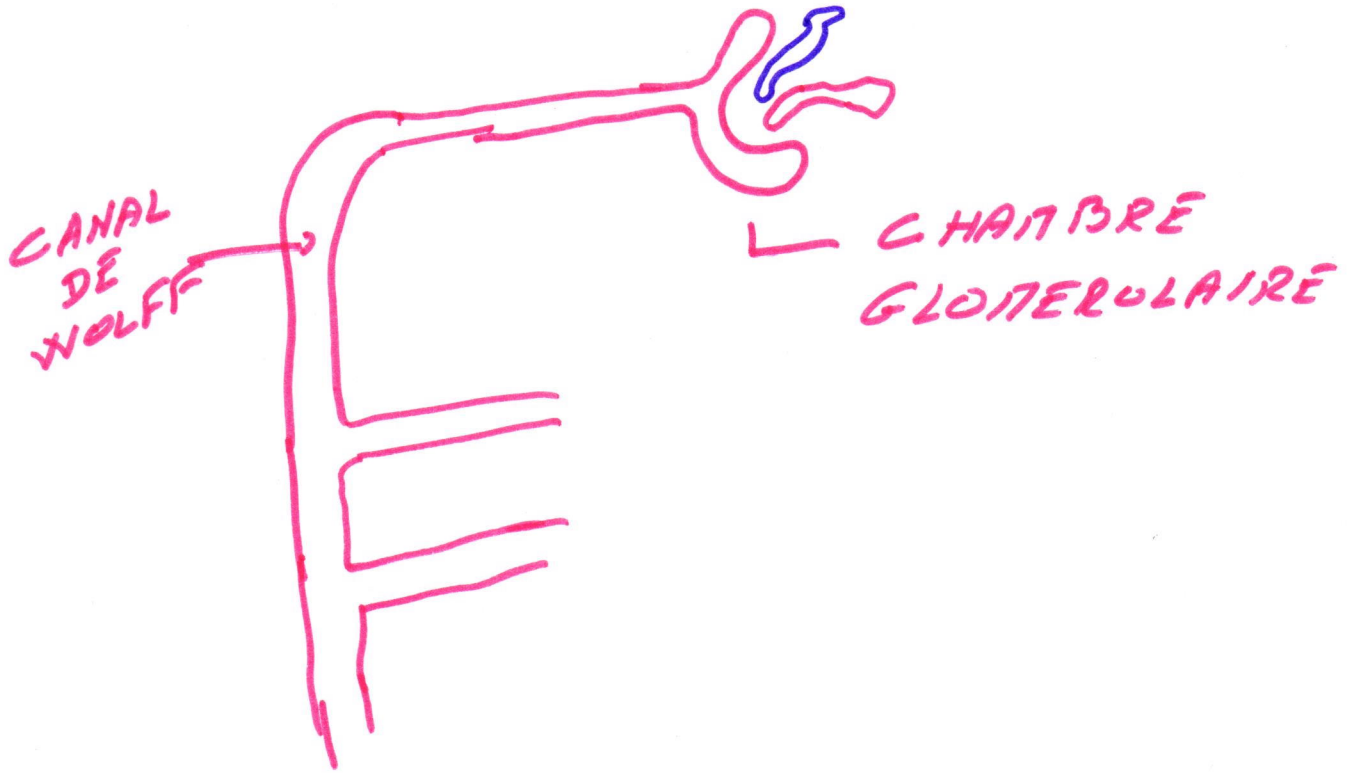
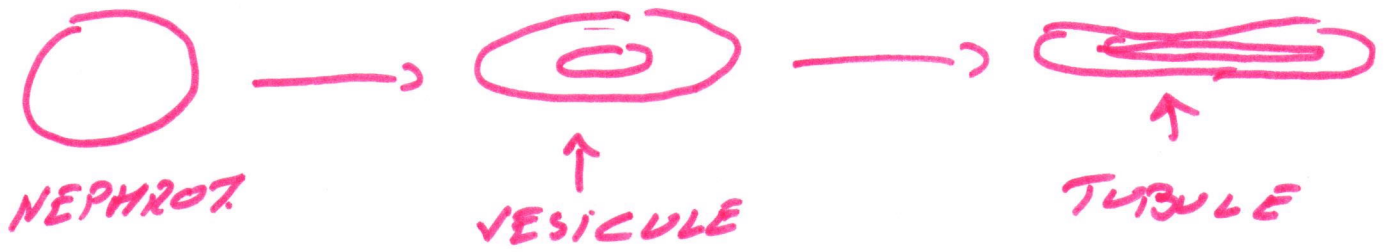
PRONEPHROS => ∅ 328



ΠΕΣΟΝΕΦΡΟΣ => 309. Νεφρολογία #



=> ΠΕΤΑΝΟΦΡΟΣ



V

